

Accuracy of the Fetal Echocardiography in the High Risk Pregnancies

B Ahmed,¹ M Stanojevic,² T Kopjar³

¹Hamad Medical Corporation, Doha, Qatar

^{2,3}Sveti Duh Hospital, Zagreb, Croatia

INTRODUCTION

When introduced in diagnostics, two-dimensional (2D) ultrasound revolutionized many fields of clinical medicine.^{1,2} Among them, the cardiology gained a huge advantage of 2D ultrasonography for postnatal diagnostics and treatment of congenital cardiac defects. Jan Donald, the father of the modern obstetrical ultrasonography, could not predict how helpful and significant ultrasonography will become for the prenatal diagnosis of fetal cardiac problems.^{1,2} About twenty-five years ago the significance of prenatal diagnosis of congenital heart defects (CHDs) was considered very important for the prognosis of the fetus, and outcome of pregnancy, possibility of the postnatal correction or lifesaving intervention and prediction of the life quality of the newborn and the family. The incidence of CHD is estimated to be 0.8 in 1000 liveborn infants, and therefore this new possibility to diagnose them prenatally, has also important public-health implications.³⁻⁵ Another question, raised but so far not solved during the development of fetal echocardiography, was that screening of CHD is necessary for all, not only for high-risk pregnancies.⁶ Very important criterion for the screening method is its simplicity, good sensitivity and specificity, acceptable reliability and low costs.^{7,8} It was revealed that sensitivity of the fetal echocardiography could be improved by visualization of four-chamber view and depiction of great arteries outflow tracts in the same fetus.⁹ Is the education of screeners alone sufficient to achieve that goal of the utmost importance for the improvement of fetal echocardiography as a screening method? The answer to that question is still unequivocal, because improvements of ultrasound technology and telemedicine are opening the new and promising possibilities even for those who are not experts.¹⁰⁻¹⁴

When introduced, three- and four-dimensional (3D and 4D) echocardiography was quite new and exciting possibility in the fetal cardiology.¹²⁻¹⁴ Medications for the rhythm disturbances of the fetal heart have been used successfully for many years. Prenatal interventions, very rarely performed on fetal heart, are becoming more available with development of new nonsurgical methods of the cardiac defect repair.¹⁵ The question is where is development of fetal cardiology headed? At the beginning of 1990s, the first trimester transabdominal or transvaginal route

of the assessment of fetal heart was developed in order to define fetal well-being and possible aneuploidy.^{6,16-21} An increasing rate of terminations of pregnancies will take place with the earlier diagnosis of CHD. In those who will survive, prenatal interventions will be possible in some cases while in the others, the prognosis will be improved by the early lifesaving postnatal intervention in the cardiac tertiary centers.^{15,22}

The aim of the chapter is to give a brief overview on development of promising field of fetal echocardiography.

DEVELOPMENT OF FETAL ECHOCARDIOGRAPHY

It was revealed in the 1980s, that fetal echocardiography could correctly predict structural malformations of the heart, and it was concluded that the technique was sufficiently reliable to give an accurate prognosis in early pregnancy and provide the basis for alterations in obstetrical management.^{3-6,9} The questions which have been raised from the early years of development of fetal echocardiography for detection of CHD, were:

- To screen or not to screen
- Whom to screen
- Who should screen, and
- When to screen.

To Screen or not to Screen for Fetal CHD ?

The answer to that question is affirmative, because sufficiently high incidence of CHD is justifying their screening.^{3-6,23-25} The screening method is relatively simple and cost effective, while the intervention after the screening could be effective. Fetal echocardiography has been a useful tool either for the prenatal detection of CHD or for the detection of other heart lesions as arrhythmias or cardiomyopathies.^{3-6,9,23-25} Most cases of CHD occur in otherwise normal pregnancies, although the risk of CHD is markedly increased in aneuploidies.^{6,11,20,26} It was revealed in the 1980s that fetal echocardiography could predict correctly structural malformations of the heart with the conclusion that the technique is sufficiently reliable to give an accurate prognosis in early pregnancy and provide the basis for alterations in obstetric management.³ In a series of 1,600 pregnancies 34 cases of CHD were correctly identified by fetal

echocardiography with the confirmation of the diagnosis by anatomical study.³ It was a great success that 14 pregnancies were terminated electively.³ Twenty fetuses died subsequently owing either to the complexity of the congenital heart disease or to associated extracardiac abnormalities.³ They reported eight errors in interpretation of the fetal echocardiogram.³ There were no reports concerning prenatal intervention on the fetal heart at that time.

In another study, the authors reported their experience with fetal CHD since 1980, when they diagnosed CHD in 1,006 fetuses.⁴ Chromosomal anomalies were more frequent in the fetuses with CHD than in the live births.⁴ The survival rate after diagnosis was poor because of frequent parental choice to interrupt pregnancy and the complexity of the disease.⁴ A large experience with fetal CHD allows good accuracy after postnatal and pathological evaluation of the prenatal findings.⁴ Knowledge of the natural history of heart malformations and their treatment allows accurate counseling offered to the parents.⁴ The parental decision in this investigation shifted toward termination of pregnancy, which means that smaller number of infants and children with complex cardiac malformations will present in postnatal life.⁴

The 1,589 infants with CHD were identified in a well-defined population.²³ The live-birth prevalence of CHD was 8.1/1000 of which only 6.1 percent were diagnosed prenatally.²³ The percentage of prenatally diagnosed CHD increased from 2.6 percent at the beginning of the investigation to 12.7 percent at the end, and it was lowest for the atrial septal defect (4.7% and highest for the hypoplastic left heart syndrome (HLHS) (28%).²³ Prenatally diagnosed CHD were associated with the high incidence of infant mortality (30.9%) and fetal wastage (17.5%).²³ Fetal echocardiography has been used increasingly in the prenatal diagnosis of congenital cardiac malformation, and it showed that survival of infants was not improved after prenatal diagnosis with fetal echocardiography.²³

Chromosomal anomalies were more frequent in fetuses with CHD.³ This tendency was confirmed by Bronshtein *et al*, who performed 12,793 transvaginal ultrasound examinations at 12th to 16th weeks of gestation of which 27 percent were considered to be at high risk for fetal CHD. Overall detection rate of CHD was 47 of 12,793 (3.6 per 1000) fetuses, of whom 29 of 9340 (3.1 per 1000) belonged to a low-risk population and 18 of 3453 (5.2 per 1000) belonged to a high risk population.⁶ Thirty-six percent of affected fetuses who underwent karyotyping had abnormal chromosomes.⁶

In a study of 1,040 fetuses at 11th to 14th weeks of gestation, Doppler velocimetry of the ductus venosus in the combination with nuchal translucency improved predictive capacity of CHD detection in chromosomally normal fetuses.²⁰ In 29 chromosomally normal fetuses, increased nuchal translucency and reversed or absent flow during atrial contraction of the ductus venosus was found, and in 9 fetal echocardiography

revealed major CHD.²⁰ A total of 25 CHD were detected in the whole population, 15 of whom were associated with aneuploidy.²⁰ They concluded that in chromosomally normal fetuses with increased nuchal translucency, assessment of ductus venosus blood flow velocimetry could improve the predictive capacity for an underlying major cardiac defect.²⁰

Extracardiac anomalies are more frequent in the group of fetuses with CHD.²⁶ In a high risk group of 334 fetuses, 48 (14.4%) were diagnosed with CHD at 12 to 17 weeks of gestation, 27 (56.3%) of whom had abnormal karyotype, and 31 (64.6%) had associated extracardiac malformations.²⁶ In the recently published retrospective study of 9918 women who were referred for fetal echocardiography, 1191 (12%) fetuses were diagnosed with CHD, of which 46 (4%) were delivered prematurely.²¹ Extracardiac and karyotypic anomalies occurred in 23 (50%). Of those 46 infants 26 (57%) underwent neonatal surgery with the overall mortality rate of 72 percent.²¹

Whom to Screen: Low Risk or High Risk Population?

The answer to that question is that CHD screening should be offered and performed in all pregnant women.²⁷ More than 90 percent of CHD occurs in low risk population.²⁷ Prenatal detection rate of CHD in tertiary perinatal centers was 18 percent and 0 percent in non-tertiary centers.²⁸ Prenatal detection rate of major CHD was 23.4 percent in the United Kingdom.²⁹

Large retrospective study with 10,806 patients in whom 774 (71,6 per 1000) cases of structural CHD were detected, revealed that the pattern of indications for fetal echocardiography has changed between 1985 and 2003.³⁰ There was a significant increase in the proportion of studies for diabetes, maternal structural CHD, suspicious 4-chamber heart, and family history of cardiac disease, while decrease of studies was noticed for a previous child with structural CHD, cardiac teratogen exposure, other fetal anomalies, aneuploidy, fetal arrhythmia, and nonimmune hydrops.³⁰

It would be interested to investigate what are prenatal detection rates of CHD in developing countries, where antenatal care is far from being satisfactory.^{31,32} Postnatal incidence of CHD in Croatia is estimated to be 7.8 in 1000 live-born infants, of which over 40 percent were detected in the first month of life and 92 percent till the end of the second year of life (Fig. 1), while the data concerning prenatal detection rate of CHD are not available.³³ Two hundred and two pregnant women with 208 fetuses of high-risk for fetal CHD, in the year 2002 underwent fetal echocardiography at "Sv. Duh" General Hospital, Zagreb, Croatia. There were 198 liveborn infants and 10 perinatal deaths: 3 stillborn, 4 early neonatal deaths and 3 induced abortions.³⁴ The most frequent indications for fetal echocardiography were: IUGR in 24, polyhydramnios in 22, pyelectasia and/or polycystic kidney disease in 22, mothers' age in 21, ultrasound markers for malformations in 20, CHD in previous pregnancy in 15, gross fetal malformations in 12, CHD or suspicious cardiac rhythm

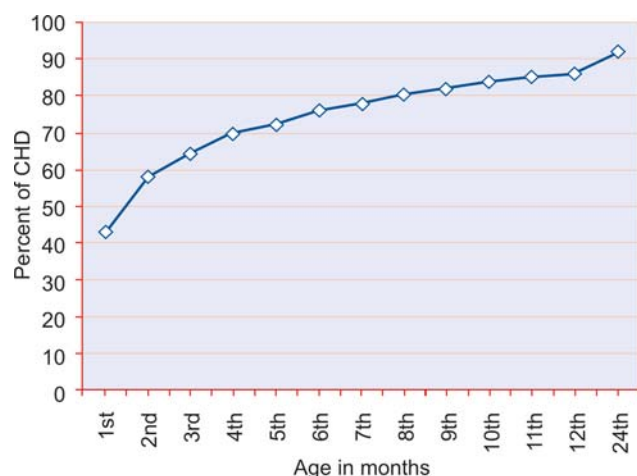


Fig. 1: Age at diagnosis of CHD in Croatia³³

disturbances on regular ultrasound examination in 9, risk of aneuploidy in 8.³⁴ In the group of three aborted fetuses with chromosomopathy and cystic hygroma two CHD were diagnosed prenatally and confirmed at autopsy postnatally.³⁴ In three stillborn fetuses neither CHD nor other congenital malformations were diagnosed, while in ten neonates who died in the early neonatal period, tricuspid regurgitation was diagnosed prenatally in one, not confirmed postnatally.³⁴

The most striking issue concerning prenatal screening of CHD is education of gynecologists performing general anomaly scan in pregnancy. As it is well-known, four-chamber view detects up to 77 percent of prenatally developed CHD, while

depiction of ventricular outflow tracts increases prenatal detection rate of CHD between 83 and 92 percent.^{6,27,35,36}

The detection of even major malformations seen in the four-chamber view is less than perfect. Some lesions could be overlooked during the examination, because four-chamber view could be normal, which does not exclude existence of CHD.^{37,38} Lesions that may be associated with normal or abnormal four-chamber view are shown in the Table 1.³⁹

Who should Screen: General Gynecologists or Pediatric Cardiologists?

In the study accuracy of prenatal diagnosis of CHD by maternal-fetal medicine specialist and radiologists (MFM/R) in the first group and pediatric cardiologists (PC) in the second group was investigated.⁴⁰ They showed that PC did significantly more fetal echocardiography scans per one normal fetus and per fetus with CHD (Table 2), which resulted in better accuracy of PC (Table 3).⁴⁰ They concluded that frequency of fetal echocardiography performed in the center may also contribute to the accuracy of the sonographer.⁴⁰

The level of agreement between obstetric and pediatric cardiologist sonographers' diagnosis of fetuses with suspected CHD was studied on 1,037 patients undergoing fetal echocardiography in a five-year period at the tertiary referral center for fetal echocardiography.⁴¹ The median gestational age at presentation was 21 weeks (range 17 to 38 weeks) with 49 percent scans performed at < 21 weeks and further, 17 percent performed at 21 to 24 weeks.⁴¹ Of 268 fetuses with CHD suspected by obstetric sonographers, 209 had confirmed cardiac defects.⁴¹ Complete correlation between obstetric

Table 1: Lesions that may be associated with an abnormal and a normal four-chamber view during fetal echocardiography³⁹

<i>Lesions that may be associated with:</i>		<i>Lesions likely to be overlooked prenatally</i>
<i>An abnormal four-chamber view</i>	<i>A normal four-chamber view</i>	
<p>At the venous atrial junction:</p> <ul style="list-style-type: none"> Total anomalous pulmonary venous drainage <p>At the atrioventricular junction:</p> <ul style="list-style-type: none"> Mitral atresia Tricuspid atresia Atrioventricular septal defect Ebstein's anomaly <p>At the ventriculo-arterial junction:</p> <ul style="list-style-type: none"> Aortic atresia Pulmonary atresia with intact interventricular septum Critical aortic stenosis Coarctation of the aorta Other Ventricular septal defect Cardiomyopathy 	<ul style="list-style-type: none"> Transposition of the great arteries Double outlet right ventricle Tetralogy of Fallot Pulmonary atresia with a ventricular septal defect Common arterial trunc Absent pulmonary valve syndrome 	<ul style="list-style-type: none"> Persistent arterial duct Secundum atrial septal defect Milder forms of obstructive lesions of great arteries Pulmonary stenosis and coarctation of the aorta Some forms of ventricular septal defects

Accuracy of the Fetal Echocardiography in the High Risk Pregnancies

Table 2: Prenatal diagnosis of CHD by maternal fetal specialists and pediatric cardiologists⁴⁰

<i>Characteristics</i>	<i>Maternal fetal medicine specialist</i>	<i>Pediatric cardiologist</i>	<i>Significance</i>
Number of fetuses	619	2147	—
Echocardiograms/fetus	1.1 ± 0.6 ²	1.6 ± 1.0	< 0.0001
Number of fetuses with CHD	34 (5,5 %)	88 (4,1%)	< 0.0001
Gestational age at diagnosis	30.4 ± 5.7	29.4 ± 5.6	NS
Extracardiac structural anomalies	35%	34%	NS

²Mean ± SD

Table 3: Postnatal confirmation of diagnosis of CHD after fetal echocardiography⁴⁰

<i>Facility</i>	<i>Correct/incorrect</i>	<i>False neg./positive</i>	<i>Diagnostic accuracy</i>
Maternal fetal medicine	25/6	3/2	87%
Pediatric cardiologist	81/4	3/2	92%*

*Statistically significant

sonographers' and pediatric cardiologists' prenatal cardiac findings was achieved in 62 percent of cases.⁴¹ The major differences were involving the atrioventricular morphology in 18 percent and outflow tract anatomy in 20 percent.⁴¹ Complete agreement between prenatal and postnatal diagnosis in fetuses with complex CHD was achieved in 59 percent of cases for obstetric sonography and 95 percent for fetal echocardiography by pediatric cardiologists with special skills in fetal echocardiography.^{25,29,41-43}

When appropriately educated gynecologists in a low risk population were involved in screening of CHD, the detection rate of 77 percent of all cardiac abnormalities, which would be associated with an abnormal appearance in four-chamber view, was achieved.⁴⁴ The maternal and fetal high risk factors with increased risk of CHD in fetuses are listed in Table 4.^{20,39} The existence of risk factors will prompt the gynecologist for referral of every suspicious case to the tertiary echocardiographic center.^{20,39,44}

There is a discussion concerning the responsibility for the prenatal screening of CHD: is it pediatric cardiologist or gynecologist responsible for the screening?^{24,25,42} There is a large discrepancy in study results of second trimester ultrasound screening for fetal malformations, owing to the different level of experience of examiners.^{24,25,42} The reported detection rates of fetal CHD were 0 to 60 percent.²⁴ Various screening concepts for more effective detection of CHD are available, and the most recent technique of early echocardiography between 11th and 15th weeks of gestation was considered very useful due to the easier termination of pregnancy if needed.^{23,24} It is our opinion that gynecologist is responsible for the screening of CHD and if CHD is suspected, than pediatric cardiologist skilled in fetal echocardiography should examine the patient and confirm or

make the diagnosis.^{29,38,43,45} Gynecologist, pediatric cardiologist, geneticist, psychologist and social worker should be involved in counseling.

When to Screen: the First or the Second Trimester?

The second trimester (usually after 18th week) is well-established and valuable investigation for the detection of CHD.^{5,9,46-48} The first trimester transabdominal and transvaginal fetal echocardiography should be performed in a high risk population.^{6,16-20,26} Weiner et al performed 329 examinations between 11th and 14th weeks, 438 examinations between 14th and 16th weeks, and 777 examinations between 20th and 24th weeks of gestation.¹⁹ Indications for the early echocardiographic scan were maternal diabetes and/or CHD in previous pregnancy.¹⁹ They diagnosed correctly 6 of 7 major fetal CHD between 11th and 14th weeks, while at that time missed one was correctly diagnosed at 22nd weeks of gestation.¹⁹ Only one of 5 minor CHD was detected between 11th and 14th weeks, and four incorrect diagnoses of minor CHD were made at the same gestational age, excluded on repeated fetal echocardiography exam at 20th and 24th weeks of gestation.¹⁹ According to Simpson *et al*, transabdominal fetal echocardiography can be performed at 12th to 15th weeks of gestation, permitting accurate early detection of major congenital heart defects in a high risk population.¹⁶ They detected 13 fetuses with CHD out of 226, and in 11 the CHD was confirmed either postnatally or at autopsy.¹⁶ Of those 213 fetuses with normal prenatal findings, CHD was detected later in pregnancy or postnatally in four (in three ventricular septal defect, and in one cardiomyopathy).¹⁶ Most echocardiographers agreed that fetal echocardiography is feasible prior to 14 weeks' gestation, and when CHD is present, than chromosomal abnormality should be suspected.^{6,16-19,26,29,49} In some studies the shift from the

Table 4: High risk factors for the development of congenital heart defects^{20, 39}

Maternal factors

- Family history (risk 2%)
- Maternal diabetes (2-3%)
- Exposure to teratogens in early pregnancy

Fetal factors

- Extracardiac fetal anomaly
- Fetal arrhythmias
- Non-immune fetal hydrops
- Increased nuchal translucency
- Abnormal ductus venosus waveforms

second to the first trimester fetal echocardiography was noted.⁷ They conclude that early fetal echocardiography is feasible and allows the detection of most CHD, but should be always followed by echocardiography at midgestation, because CHD vary in appearance at different stages of pregnancy and may evolve *in utero* with advancing gestational age.⁷ According to some investigators, the success rate of early fetal echocardiography depends on gestational age as follows: the complete evaluation of the fetal heart was impossible at 10th week, the total success rate was 45 percent at 11th week, 90 percent between 12th and 14th weeks and 100 percent at 15th week of gestation.⁵⁰ Between 10th and 13th weeks transvaginal approach was superior to transabdominal, at 14th week both methods were similar, and at 15 weeks transabdominal sonography enabled visualization of all cardiac structures.⁵⁰ Complete evaluation of fetal heart included: total heart diameter, heart area and circumference, right and left ventricular diameter, diameter, area and circumference of the thorax, and diameter of the aorta and pulmonary trunk, visualization of four- and five-chamber view (Figs 2 and 3), 3-vessel view, origin and crossover of the great arteries, aortic arch (Fig. 4), ductus arteriosus, superior and inferior vena cavae and pulmonary veins.⁵⁰ Figure 5 shows parasternal short axis view with depiction of the main pulmonary artery and its branches and aorta.

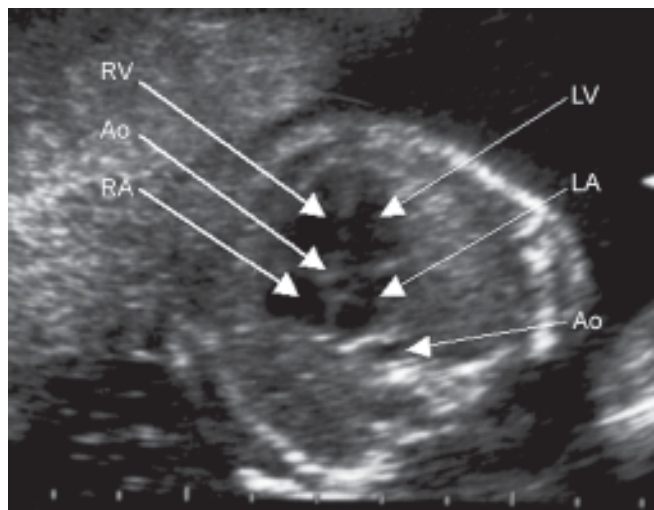


Fig. 3: Apical five-chamber view (17th week)

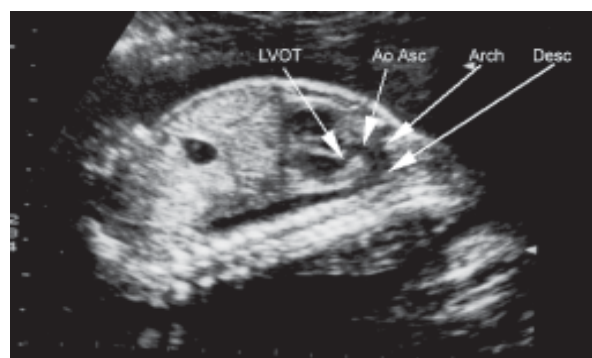


Fig. 4: Aortic arch—sagittal view (18th week)
LVOT = left ventricular outflow tract, Ao = aorta
Asc = ascending, Desc = descending

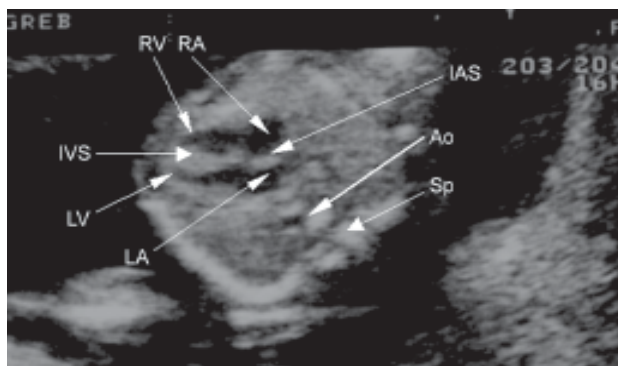


Fig. 2: Lateral four-chamber view (apical long axis view at 17th week)

RV = right ventricle RA = right atrium LV = left ventricle LA = left atrium IAS = interatrial septum IVS = intraventricular septum Ao = aorta Sp = spine

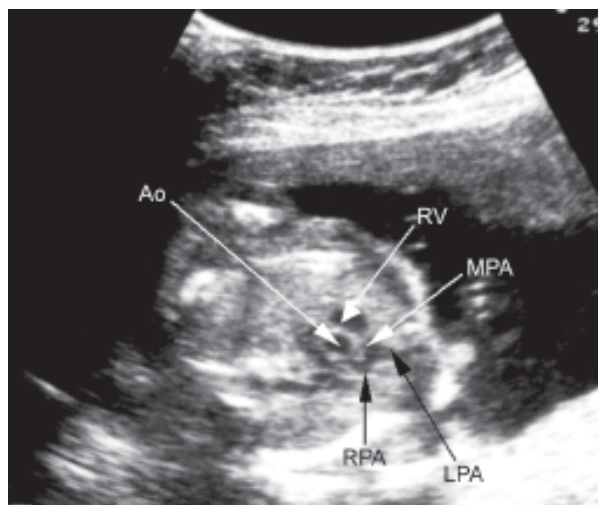


Fig. 5: Parasternal short axis view of the right ventricle outflow tract (18th week)

Ao = aorta RV = right ventricle MPA = main pulmonary artery RPA= right pulmonary artery LPA = left pulmonary artery

WHAT AFTER THE PRENATAL DIAGNOSIS OF FETAL CARDIAC LESION?

The CHD accounts for 9 percent of infant mortality in the UK and about 200 infants die each year of undiagnosed CHD.⁵¹ One of the reasons for the growth of fetal echocardiography programs in many developed countries is to decrease the incidence of undiagnosed CHD. It is clear that in the right hands fetal echo has a high sensitivity and specificity. However, it is dependent on an efficient referral system. This necessitates close cooperation between obstetric sonographers and pediatric cardiologists.⁵¹ Fetal echocardiography has its limitations in terms of detection of more minor, yet significant CHD, and is relatively time consuming.⁵¹

The most common cardiac lesions detected prenatally in the fetus, shown in Figure 6, are: atrioventricular septal defect, hypoplastic left heart syndrome, ventricular septal defect, coarctation of the aorta, tricuspid atresia, and other lesions.³⁹

The outcome of cardiac malformations diagnosed prenatally according to Sharland, is in over half of diagnosed fetuses termination of pregnancy, while in the next 30 percent intrauterine, neonatal or infant death occurred.³⁹ Overall termination of pregnancy rate is about 80 percent while survival rate is as low as 20 percent.³⁹ The termination of pregnancy rate is decreasing in the observed period of time, while the opposite tendency is observed with the survival rate of babies from pregnancies that have continued after the diagnosis of CHD (Figs 7 and 8).³⁹

Prenatal diagnosis of structural CHD is associated with a poor prognosis.⁴⁵ High mortality rate of 79 percent has been reported in the study of 222 fetuses, infants and children in whom prenatal diagnosis of CHD was made.⁴⁵ Prenatal death occurred in 57 fetuses, 87 died as neonates and 31 died in infancy and childhood.⁴⁵ Among 47 survivors only five have survived beyond four years.⁴⁵ High mortality was associated with the presence of extracardiac anomalies in 32 percent and prenatal cardiac failure in 13 percent.⁴⁵ Fetal echocardiography has been a useful tool for prenatal detection of CHD and other heart lesions, and in some cases for the treatment of fetal arrhythmias.⁴⁶ As the most forms of heart disease occur in otherwise normal pregnancies with no high-risk features, detection of these cases is dependent on the skill of the ultrasonographer performing general obstetric scanning.⁴⁶ Detection of even major malformations seen in the four-chamber view is still less than perfect.^{46,47} It is expected that CHD will be detected earlier in pregnancy and examination will include evaluation of the great artery structure.⁴⁷ There is now evidence that prenatal diagnosis of CHD improves perinatal morbidity or mortality.⁴⁸ New information about the molecular genetic basis of CHD will help in management and counseling.⁴⁸ If extracardiac malformations are excluded, than *in utero* therapy should be considered for some malformations.⁴⁸ It was available for fetal

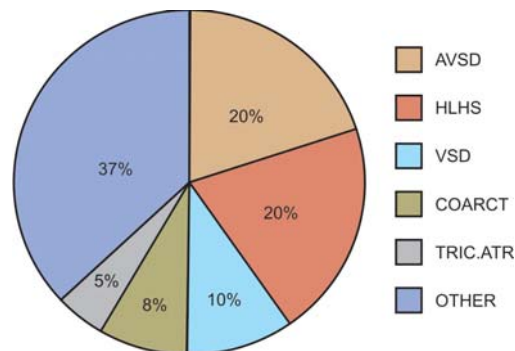


Fig. 6: Incidence of CHD detected by fetal echocardiography³⁹
 AVSD: Atrioventricular septal defect
 HLHS: Hypoplastic left heart syndrome
 VSD: Ventricular septal defect
 COARCT: Coarctation of the aorta
 TRIC. ATR: Tricuspid atresia

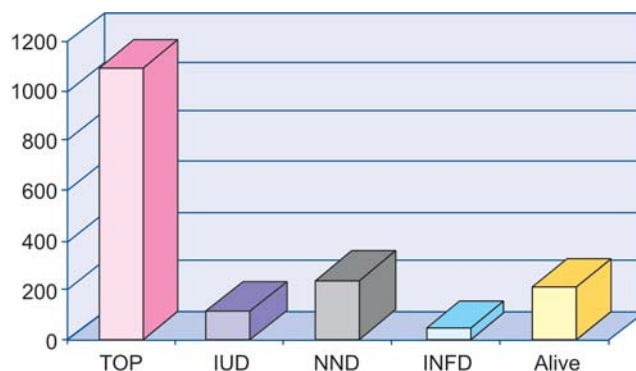


Fig. 7: The outcome of cardiac malformations diagnosed prenatally³⁹
 TOP: Termination of pregnancy; IUD: Intrauterine death; NND: Neonatal death, INF: Infant death

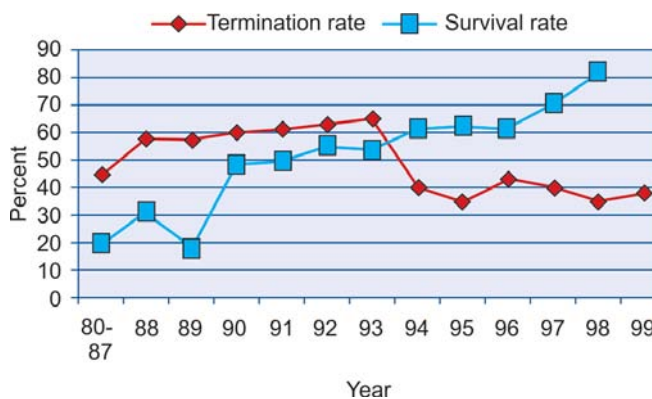


Fig. 8: The outcome of prenatally detected CHD (modified according to 39)

arrhythmias, fetal heart failure, and in some cases for very few structural CHD.^{15,39}

The majority of neonates who have CHD will not require delivery room resuscitation in excess of routine care.²² However, resuscitation could be required in a small number of prenatally diagnosed CHD including transposition of the great arteries with intact ventricular and restrictive atrial septum, hypoplastic left heart syndrome with intact atrial septum, obstructed total anomalous pulmonary venous return, and complete congenital heart bloc.²²

The outcome after prenatal diagnosis of the hypoplastic left heart syndrome (HLHS) in 30 fetuses was as follows: 4 of 12 mothers whose fetuses were diagnosed before 24th week of gestation choose the termination of pregnancy.⁵² Intention to treat was in 24 of the remaining fetuses, of whom 5 were not offered Norwood stage 1 procedure, because of trisomy 18, unfavorable cardiac anatomy or neurological impairment.⁵² Of 18 patients who were selected for the operation, nine survived, which means that survival rate was 37.5 percent from an intention to treat position.⁵² It was concluded that survival rate of the patients with the HLHS is poor and discouraging.⁵²

The survival after fetal aortic and pulmonary balloon valvuloplasty has been reported, and seemed very encouraging approach to the treatment of the fetal CHD.^{15,53} The world discouraging experience of percutaneous ultrasound-guided balloon valvuloplasty in human fetuses with severe aortic valve obstruction was reported in 12 fetuses between 27th and 33rd weeks of gestation.⁵⁴ The range between initial presentation and intervention was 3 days to 9 weeks. Technically successful balloon valvuloplasties were achieved in 7 fetuses, none of whom had atretic valve.⁵⁴ Only one of these 7 fetuses survived, while remaining 6 died postnatally due to cardiac dysfunction or at surgery in the early postnatal period.⁵⁴ The conclusion was that the experience with fetal ultrasound-guided balloon valvuloplasty has been poor due to selection of severe cases and technical problems during the procedure.⁵⁴

NEW IMAGING TECHNIQUES FOR THE EVALUATION OF FETAL HEART

In order to improve fetal cardiac diagnosis, new techniques have been developed for better evaluation of fetal heart.¹⁴ These techniques can provide:

- Sequential assessment of the entire heart using a full 4D dataset
- 4D delineation of trabeculation patterns on the ventricular walls, en-face dynamic shapes of ventricular septal defects and spatially complex malformations
- Derivation of cardiac indices to myocardial contractility and strain rate by Doppler tissue imaging, and/or
- Use of transoesophageal ultrasound to guide *in utero* cardiac intervention.

These techniques are: dynamic three-dimensional or four-dimensional (4D) echocardiography, myocardial Doppler imaging, B-flow ultrasonography, endoscopic ultrasound, and magnetic resonance imaging.¹⁴ Of them, 4D echocardiography includes real-time volumetric data acquisition using matrix-array transducer technology, motion artifact elimination using spatiotemporal image correlation (STIC), and various display options. STIC offers an easy to use technique to visualize fetal heart in a 4D sequence.¹² The acquisition is performed in two steps. First, data is acquired by a single, automatic volume sweep. In the second step, the system analyzes the data according to their spatial and temporal domain and processes a 4D sequence.¹² This sequence presents the heart beating in real time in a multiplanar display.¹² The examiner can navigate within the heart, re-slice, and produce all the standard planes necessary for comprehensive diagnosis.¹² This new modality enables to obtain the volume of data which can be manipulated along the x- and y-axes using reference points from the four-chamber view, five-chamber-view, three-vessel view with depiction of ventricular outflow tracts.⁵⁵ The multiplanar evaluation of fetal heart allows the easier identification of fetal cardiac structures during “off-line” analysis by a simple technique of heart volume rotation around different axes.⁵⁵ A new technology, tomographic ultrasound imaging (TUI), allows the examiner to obtain a volume data set that simultaneously displays multiple images at specific distances from the 4-chamber view.⁵⁶ TUI technology is capable for identifying normal and abnormal fetal cardiac anatomy with the use of either static or spatiotemporal image correlation volume data sets (Figs 9 and 10).⁵⁶




Fig. 9: Tomographic ultrasound imaging—static image correlation volume data set of the left ventricular outflow tract (LVOT)

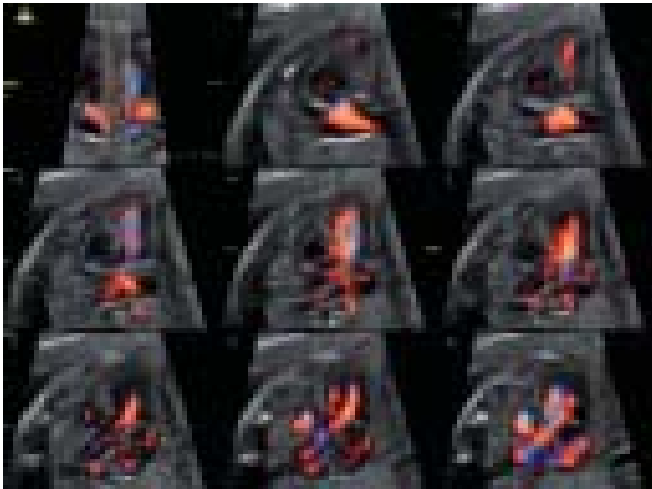


Fig. 10: Tomographic ultrasound imaging with color Doppler—static image correlation volume data set of the left and the right ventricular outflow tracts

CONCLUSION

Are improvements in the field of the fetal echocardiography possible? The answer should be confirmative, because in the last two decades there were so many new facts concerning the pathophysiology and the management of the cardiac diseases. The shift from the prenatal diagnosis of the structural cardiac anomalies and rhythm disturbances toward the fetal cardiac flow dynamics has been made owing to the development of sophisticated ultrasound techniques in hands of skilled professionals.^{27,57} Improvements from the point of view of the public health could be achieved in better screening protocols, broadly performed by more skilled professionals in earlier gestational ages.⁵⁸⁻⁶⁰ Increasing role of 3D or live 3D ultrasonography, and telemedicine are promising fields of the development of fetal echocardiography, with the possibility to improve detection rate and accuracy of prenatal CHD diagnosis.^{9-11,61-66} Goal of the development of fetal echocardiography should be to increase prenatal detection rate of most hemodynamically significant CHD in early pregnancy in order to decrease late diagnosis of CHD postnatally. After the diagnosis of the CHD, the appropriate multidisciplinary counseling should be offered with the development of effective treatment. Genetic counseling and the gene treatment in some cases of CHD are probably the future challenges of the fetal cardiology.⁵⁸ The past, when the first diagnosis of CHD was made prenatally, predicted the future of the growing field of fetal cardiology, which is so promising, dynamic and challenging.

REFERENCES

1. Newman PG, Rozycki GS. The history of ultrasound. *Surg Clin North Am* 1998;78:179-95.
2. McNay MB, Fleming EE. Forty years of obstetric ultrasound 1957-1997: from A-scope to three dimensions. *Ultrasound Med Biol* 1999;25:3-56.
3. Allan LD, Crawford DC, Anderson RH, Tynan MJ. Echocardiographic and anatomical correlations in fetal congenital heart disease. *Br Heart J* 1984;52:542-8.
4. Allan LD, Sharland GK, Milburn A, Lockhart SM, Groves AM, Anderson RH, Cook AC, Fagg NL. Prospective diagnosis of 1,006 consecutive cases of congenital heart disease in the fetus. *J Am Coll Cardiol* 1994;23:1452-8.
5. Barboza JM, Dajani NK, Glenn LG, Angtuaco TL. Prenatal diagnosis of congenital cardiac anomalies: a practical approach using two basic views. *Radiographics* 2002;22:1125-37.
6. Bronshtein M, Zimmer EZ, Gerlis LM, Lorber A, Drugan A. Early ultrasound diagnosis of fetal congenital heart defects in high-risk and low risk pregnancies. *Obstet Gynecol* 1993;82:225-9.
7. Smrcek JM, Berg C, Geipel A, Fimmers R, Axt-Fliedner R, Diedrich K, Gembruch U. Detection rate of early fetal echocardiography and *in utero* development of congenital heart defects. *J Ultrasound Med* 2006;25:187-96.
8. Odibo AO, Coassolo KM, Stamilio DM, Ural SH, Macones GA. Should all pregnant diabetic women undergo a fetal echocardiography? A cost-effectiveness analysis comparing four screening strategies. *Prenat Diagn* 2006;26:39-44.
9. Carvalho JS, Mavrides E, Shinebourne EA, Campbell S, Thilaganathan B. Improving the effectiveness of routine prenatal screening for major congenital heart defects. *Heart* 2002;88:387-91.
10. Jurgens J, Chaoui R. Three-dimensional multiplanar time-motion ultrasound or anatomical M-mode of the fetal heart: a new technique in fetal echocardiography. *Ultrasound Obstet Gynecol* 2003;21:119-23.
11. Sharma S, Parness IA, Kamenir SA, Ko H, Haddow S, Steinberg LG, Lai WW. Screening fetal echocardiography by telemedicine: efficacy and community acceptance. *J Am Soc Echocardiogr* 2003;16:202-8.
12. DeVore GR, Falkensammer P, Sklansky MS, Platt LD. Spatiotemporal image correlation (STIC): new technology for evaluation of the fetal heart. *Ultrasound Obstet Gynecol* 2003;22:380-7.
13. Yagel S, Silverman NH, Gembruch U (Eds). *Fetal Echocardiography*. Martin Dunitz Taylor & Francis Group, London, New York, 2003.
14. Deng J, Rodeck CH. Current applications of fetal cardiac imaging technology. *Curr Opin Obstet Gynecol* 2006;18:177-84.
15. Galindo A, Gutierrez-Larraya F, Velasco JM, de la Fuente P. Pulmonary balloon valvuloplasty in a fetus with critical pulmonary stenosis/atresia with intact ventricular septum and heart failure. *Fetal Diagn Ther* 2006;21:100-4.
16. Simpson JM, Jones A, Callaghan N, Sharland GK. Accuracy and limitations of transabdominal fetal echocardiography at 12-15 weeks of gestation in a population at high risk for congenital heart disease. *Br J Obstet Gynecol* 2000;107:1492-7.
17. Huggon IC, Ghi T, Cook AC, Zosmer N, Allan LD, Nicolaidis KH. Fetal cardiac abnormalities identified prior to 14 weeks' gestation. *Ultrasound Obstet Gynecol* 2002;20:22-9.

18. Martinez JM, Gomez O, del Rio M, Puerto B, Borrell A, Cararach V, Fortuny A. Early fetal echocardiography: a new challenge in prenatal diagnosis. *Ultrasound Rev Obstet Gynecol* 2002;2:251-60.
19. Weiner Z, Lorber A, Shalev E. Diagnosis of congenital cardiac defects between 11 and 14 weeks' gestation in high-risk patients. *J Ultrasound Med* 2002;21:23-9.
20. Favre R, Cherif Y, Kohler M, Kohler A, Hunsinger MC, Bouffet N, Tonghe M, Cancellier M, Nisand I. The role of fetal nuchal translucency and ductus venosus Doppler at 11-14 weeks of gestation in the detection of major congenital heart defects. *Ultrasound Obstet Gynecol* 2003;21:239-43.
21. Andrews RE, Simpson JM, Sharland GK, Sullivan ID, Yates RW. Outcome after preterm delivery of infants antenatally diagnosed with congenital heart disease. *J Pediatr* 2006;148:213-6.
22. Johnson BA, Ades A. Delivery room and early postnatal management of neonates who have prenatally diagnosed congenital heart disease. *Clin Perinatol* 2005;32:921-46.
23. Monatna E, Khoury MJ, Cragan JD, Sharma S, Dhar P, Fyfe D. Trends and outcomes after prenatal diagnosis of congenital cardiac malformations by fetal echocardiography in a well-defined birth population, Atlanta, Georgia, 1990-1994. *J Am Coll Cardiol* 1996;28:1805-9.
24. Gambruch U. Prenatal diagnosis of congenital heart disease. *Prenat Diagn* 1997;17:1283-98.
25. Allan LD. Fetal congenital heart disease: diagnosis and management. *Curr Opin Obstet Gynecol* 1994;6:45-9.
26. Comas Gabriel C, Galindo A, Martinez JM, Carrera JM, Gutierrez-Laraya F, de la Fuente P, Puerto B, Borell A. Early prenatal diagnosis of major cardiac anomalies in a high risk population. *Prenat Diagn* 2002;22:586-93.
27. Bega G, Kuhlman K, Lev-Toaff A, Kurtz A, Wapner W. Application of three-dimensional ultrasonography in the evaluation of the fetal heart. *J Ultrasound Med* 2001;20:307-13.
28. American Institute of Ultrasound in Medicine. Performance of basic fetal cardiac ultrasound examination (technical bulletin). *J Ultrasound Med* 1998;17:601-7.
29. Friedman AH, Kleinman CS, Copel JA. Diagnosis of cardiac defects: where we've been, where we are and we're going? *Prenat Diagn* 2002;22:280-4.
30. Hamar BD, Dziura J, Friedman A, Kleinman CS, Copel JA. Trends in fetal echocardiography and implications for clinical practice: 1985 to 2003. *J Ultrasound Med* 2006;25:197-202.
31. Drazancic A. Antenatal care in developing countries. What should be done? *J Perinatal Med* 2001;29:188-98.
32. Kurjak A, Bekavac I. Perinatal problems in developing countries: lessons learned and future challenges. *J Perinat Med* 2001;29:179-87.
33. Malèia I, Rojnia-Putarek N, Rudan I. Epidemiologija prirođenih srèanih grešaka u Hrvatskoj – multicentrièna nacionalna studija; privremeno izvješæe. In: Malèia I. Pedijatrijska kardiologija – odabrana poglavlja: Medicinska naklada, Zagreb, 2001:30-42.
34. Stanojevic M, Kurjak A. From fetal to neonatal echocardiography: does it predict the future? *Ultrasound Rev Obstet Gynecol* 2003;3:150-9.
35. Crane JP, Lefevre ML, Winborn RC, et al. Randomized trial of prenatal ultrasound screening: impact on detection, management and outcome of anomalous fetuses. The RADIUS study group. *Am J Obstet Gynecol* 1995;172:1641-2.
36. Bull C on behalf of British Paediatric Cardiac Association. Current and potential impact of fetal diagnosis on prevalence and spectrum of serious congenital heart disease at term in the UK. *Lancet* 1999;354:1242-7.
37. Mapp T. Fetal echocardiography and congenital heart disease. *Prof Care Mother Child* 2000;10:9-11.
38. Allan LD. A practical approach to fetal heart scanning. *Semin Perinatol*. 2000;24:324-30.
39. Sharland G. Fetal cardiology. *Semin Neonatol* 2001;6:3-15.
40. Berghella V, Pagotto L, Kaufman M, Huhta JC. Accuracy of prenatal diagnosis of congenital heart defects. *Fetal Dign Ther* 2001;16:407-12.
41. I. Pedijatrijska kardiologija – odabrana poglavlja: Medicinska naklada, Zagreb, 2001:30-42.
42. Stanojevic M, Kurjak A. From fetal to neonatal echocardiography: does it predict the future? *Ultrasound Rev Obstet Gynecol* 2003;3:150-9.
43. Crane JP, Lefevre ML, Winborn RC, et al. Randomized trial of prenatal ultrasound screening: impact on detection, management and outcome of anomalous fetuses. The RADIUS study group. *Am J Obstet Gynecol* 1995;172:1641-2.
44. Bull C on behalf of British Paediatric Cardiac Association. Current and potential impact of fetal diagnosis on prevalence and spectrum of serious congenital heart disease at term in the UK. *Lancet* 1999;354:1242-7.
45. Mapp T. Fetal echocardiography and congenital heart disease. *Prof Care Mother Child* 2000;10:9-11.
46. Allan LD. A practical approach to fetal heart scanning. *Semin Perinatol*. 2000;24:324-30.
47. Sharland G. Fetal cardiology. *Semin Neonatol* 2001;6:3-15.
48. Berghella V, Pagotto L, Kaufman M, Huhta JC. Accuracy of prenatal diagnosis of congenital heart defects. *Fetal Dign Ther* 2001;16:407-12.
49. Mayer-Wittkopf M, Cooper S, Sholler G. Correlation between fetal cardiac diagnosis by obstetric and pediatric cardiologist sonographers and comparison with postnatal findings. *Ultrasound Obstet Gynecol* 2001;17:392-7.
50. Tuzler G. Fetal cardiology. *Curr Opin Pediatr* 2000;12:492-6.
51. Penny DJ, Weintraub RG. Fetal echocardiography. *J Pediatr Child Health* 1995;31:371-4.
52. Sharland G, Allan LD. Screening for congenital heart disease prenatally. Results of a 2 year study in the south-east Thames Region. *Br J Obstet Gynecol* 1992;99:220-5.
53. Sharland GK, Lockhart SM, Chita SK, Allan LD. Factors influencing the outcome of congenital heart disease detected prenatally. *Arch Dis Child* 1991;66:284-7.
54. Mapp T. Fetal echocardiography and congenital heart disease. *Prof Care Mother Child* 2000;10:9-11.
55. Allan LD. The outcome of fetal congenital heart disease. *Semin Perinatol* 2000;24:380-4.
56. Todros T. Prenatal diagnosis and management of fetal cardiovascular malformations. *Curr Opin Obstet Gynecol* 2000;12:105-9.

57. Carvalho JS, Moscoso G, Ville Y. First-trimester transabdominal fetal echocardiography. *Lancet* 1998;351:1023-7.
58. Smrcek JM, Berg C, Geipel A, Fimmers R, Diedrich K, Gembruch U. Early fetal echocardiography: heart biometry and visualization of cardiac structures between 10 and 15 weeks' gestation. *J Ultrasound Med* 2006;25:173-82.
59. Sands A, Craig B, Mulholland C, Patterson C, Dornan J, Casey F. Echocardiographic screening for congenital heart disease: a randomized study. *J Perinat Med* 2002;30:307-12.
60. Allan LD, Apfel HD, Printz BF. Outcome after prenatal diagnosis of the hypoplastic left heart syndrome. *Heart* 1998;79:371-3.
61. Allan LD, Maxwell DJ, Carminati M, Tynan MJ. Survival after fetal aortic balloon valvuloplasty. *Ultrasound Obstet Gynecol* 1995;5:90-1.
62. Kohl T, Sharland G, Allan LD, Gembruch U, Chaoui R, Lopes LM, Zielinsky P, Huhta J, Silverman NH. World experience of percutaneous ultrasound-guided balloon valvuloplasty in human fetuses with severe aortic valve obstruction. *Am J Cardiol* 2000;85:1230-3.
63. Devore GR, Polanco B, Sklansky MS, Platt LD. The 'spin' technique: a new method for examination of the fetal outflow tracts using three-dimensional ultrasound. *Ultrasound Obstet Gynecol* 2004;24:72-82.
64. Devore GR, Polanco B. Tomographic ultrasound imaging of the fetal heart: a new technique for identifying normal and abnormal cardiac anatomy. *J Ultrasound Med* 2005;24:1685-96.
65. Michailidis GD, Simpson JM, Karidas C, Economides DL. Detailed three-dimensional fetal echocardiography facilitated by an internet link. *Ultrasound Obstet Gynecol* 2001;18:325-8.
66. Saiki Y, Rebeyka IM. Fetal cardiac intervention and surgery. *Semin Thorac Cardiovasc Surg Pediatr Card Surg Annu* 2001;4:256-70.