

# Ultrasonographic Evaluation of Fetal Face by 3D/4D Sonography

<sup>1</sup>Guillermo Azumendi, <sup>2</sup>Iva Lausin, <sup>2</sup>Asim Kurjak, <sup>3</sup>Ritsuko K Pooh, <sup>1</sup>Gaston Grant

<sup>1</sup>Clinica Ecografia, Centro Gutenberg, Malaga, Spain

<sup>2</sup>Department of Obstetrics and Gynecology, Medical School University of Zagreb, Sveti Duh Hospital, Zagreb, Croatia

<sup>3</sup>CRIFM Clinical Research Institute of Perinatal Medicine, Osaka, Japan

Tel: +81-(0)-6-6775-8111, e-mail: rkpooh@guitar.ocn.ne.jp

**Abstract:** The evaluation of the fetal face is an important part of every ultrasound examination since detailed facial examination can provide many information alerting the examiner about possible associated anomalies. Face and the brain have the same embryonic origin. By using 2 and 3D ultrasound techniques, it is possible to obtain clear images of different fetal face defects. Incorporation of the 4D ultrasonography made it possible to examine fetal behavior including fetal face movements. In that way using the ultrasound in the examination of the fetal face provides many new information not just about the morphology but also about neurological development and function of the fetal face.

**Keywords:** Fetal face, fetal behavior, cerebral palsy.

## INTRODUCTION

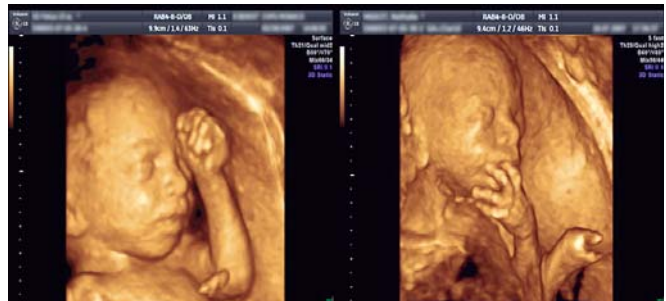
It is frequently said that face predicts the brain and that it is a mirror of the brain.<sup>1</sup> The evaluation of the fetal face by using 3D and 4D sonography is discussed elsewhere.<sup>2-6</sup> It is the purpose of this review to analyze both structural and functional development of fetal face connected with exciting new field of fetal neurology.

The development of the face and its related structures takes place in the embryonic period. By the end of 6th week there is a visual evidence of development, and by the end of the eight week, the face has characteristics that allow its identification as human.<sup>7-9</sup> During the fetal period, examination of the fetal face by ultrasound is facilitated by the presence of the surrounding fluid.<sup>10</sup>

Most experts perform a qualitative evaluation of the fetal face by using a 2 dimensional ultrasonography (2DUS), but incorporation of the 3 dimensional ultrasound (3DUS) technology into clinical practice has resulted in great progress in visualization and anatomy examination of the fetal face. Four dimensional ultrasonography (4DUS) provided for the first time an opportunity to evaluate subtle fetal face expressions which can be used to understand fetal behavior.<sup>2,10-14</sup>

3DUS shows perspectives that cannot be obtained with 2DUS and depicts the anatomy in the most appropriate and comprehensive position.<sup>15</sup> Because of the curvature and small anatomical details, the fetal face can be visualized and analyzed only to a limited extent using 2D sonography. The entire face cannot be seen on a single image. 3DUS provides spatial reconstruction of fetal face and simultaneous visualization of

all facial structures such as the fetal nose, eyebrows, mouth, and eyelids (Fig. 1).<sup>16</sup> Volume recorded by using 3DUS technique can be reconstructed afterwards by using some of the possible rendering modes.



**Fig. 1:** 3D image shows small anatomical face details; fetal face in the second half of the pregnancy

4D ultrasound has some additional advantages as the ability to study fetal activity in the surface rendered mode and is particularly superior for fast fetal movements (Fig. 2).<sup>16,17</sup>

4DUS makes it possible relatively easy to see different facial movements including jaw movements, laughing, jawing, eye opening and eyes movements. Many new studies have purposed knowledge about evaluation of function of the fetal brain and neurological development based on examination of fetal movements, including the fetal face.<sup>14,17-20</sup> Two-dimensional real-time ultrasound and four-dimensional sonography are complementary methods used for the evaluation of fetal movements.

## NORMAL FACIAL DEVELOPMENT

By the end of the eight week fetal face can be visualized using ultrasound but flexion of the cranial part of embryo can make it difficult.<sup>21,22</sup> From the 9th week, the head is clearly divided from the body by the neck. In the week 11 and 12 structures like nose, orbits, maxilla, mandible and mouth can be observed (Fig. 3). Around 13th week structures of the face are developed enough and can be evaluated in diagnostics purposes (Fig. 4).<sup>3</sup>

The human face is unique in that each individual has distinct, individually recognizable features. Formation of the face is

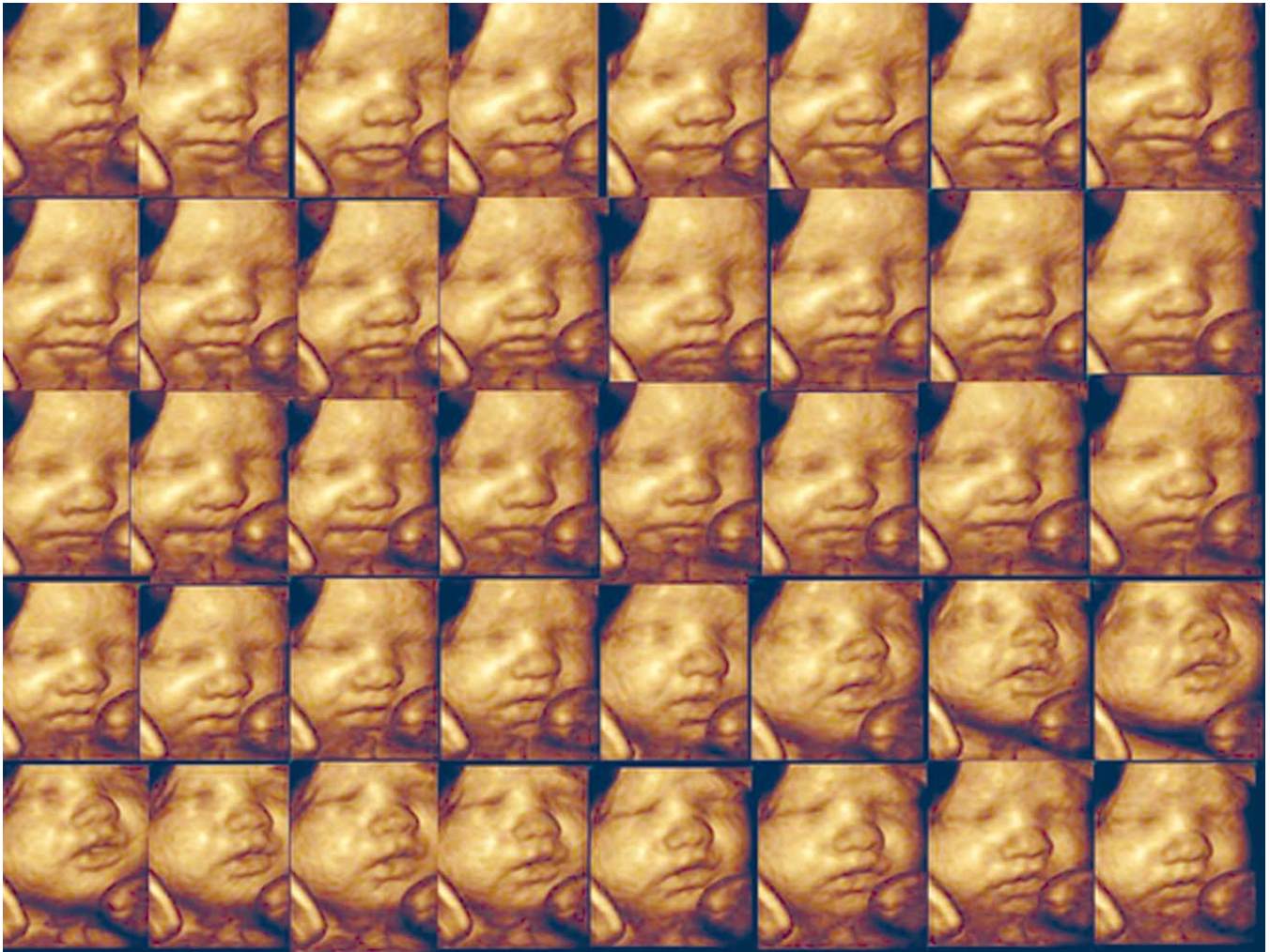

Fig. 2: 4D ultrasound enables a display in fast real time

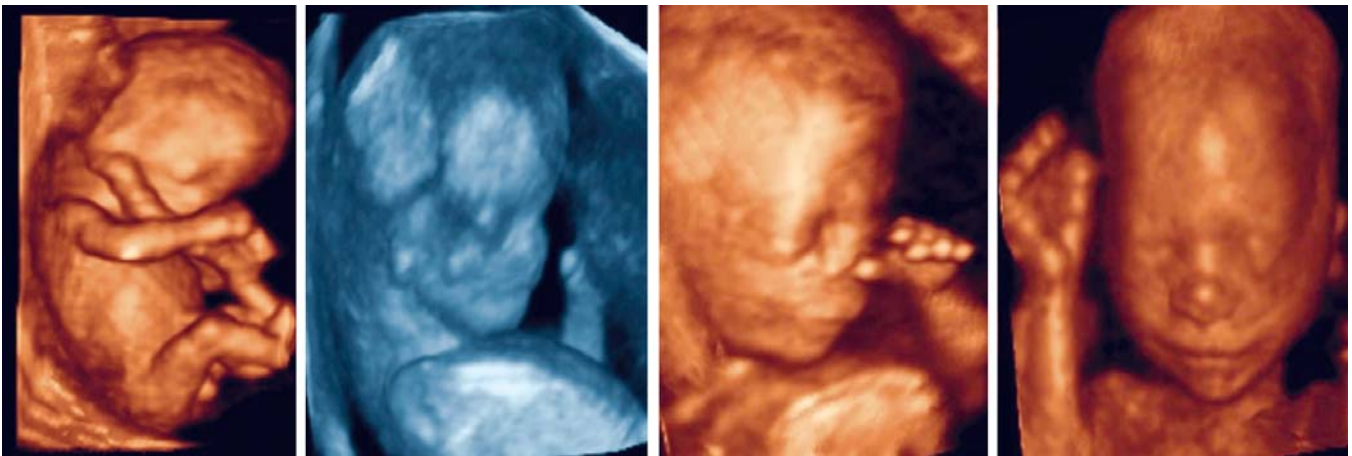

Fig. 3: Fetal face in first half of the pregnancy: 10th, 12th, 14th and 18th week

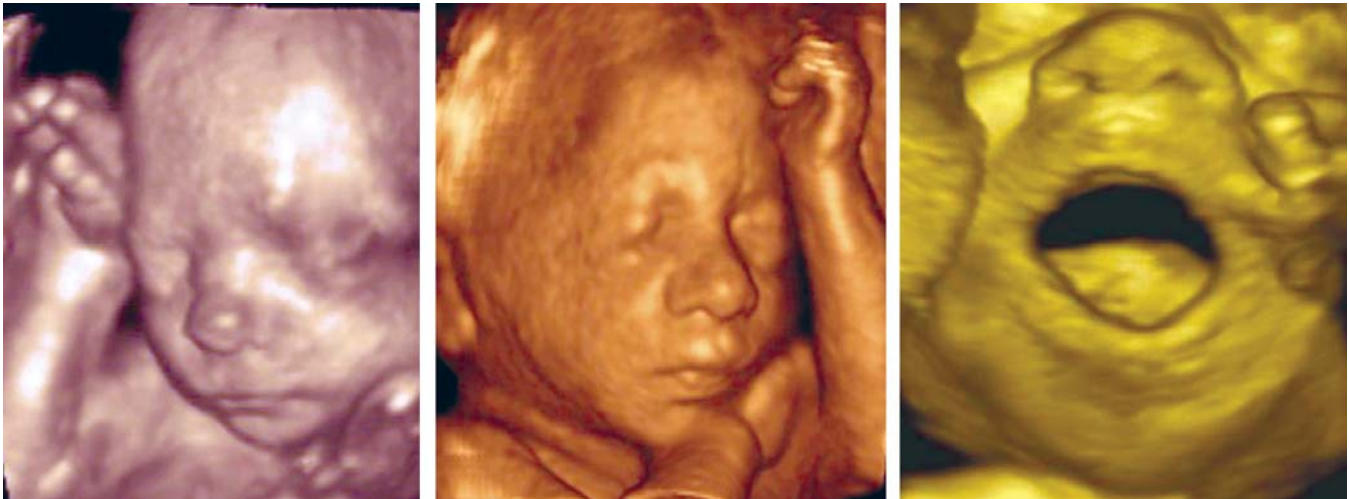

Fig. 4: Fetal face in the second half of the pregnancy

embryologically complex, and continuous growth and remodeling is not complete until post-puberty.<sup>8</sup>

At the end of week 4, the stomodeum forms the center of the face and is surrounded by 5 facial prominences. The maxillary prominences are lateral to the stomodeum and the mandibular prominences caudal to the stomodeum. Both develop from neural crest derived mesenchyme from the 1st pharyngeal arch. The 5th prominence, the frontonasal prominence, develops from proliferating mesenchyme ventral to the brain vesicles and is located above (cranial to) the stomodeum.<sup>8,9,22</sup>

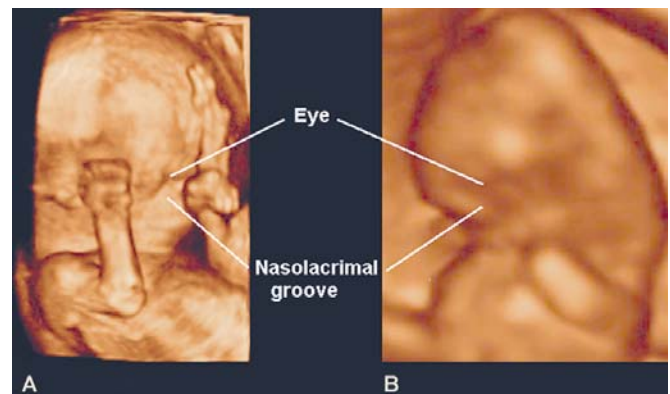
On both sides of frontonasal prominence, two thickenings can be observed—the nasal placodes. During week 5, the nasal placodes invaginate to form nasal pits, creating a ridge of tissue surrounding each pit, forming the medial and lateral nasal prominences. During the next 2 weeks, the maxillary prominences enlarge and grow medially, compressing the medial nasal prominence towards the midline. The cleft between the maxillary and medial nasal prominence is lost and the two fuse forming the upper lip. The lateral nasal prominence does not take part in the formation of the lip. The lower lip and jaw are formed by the mandibular prominence.<sup>8,9,22</sup>

Initially the maxillary and the lateral nasal prominences are separated by the nasolacrimal groove. The ectoderm in the floor of the groove forms a solid epithelial cord and detaches from the overlying ectoderm (Fig. 5). It canalizes to form the nasolacrimal duct. After detachment of the cord, the maxillary and lateral nasal prominences merge with each other. The maxillary prominences then enlarge to form the cheeks and maxillae.<sup>8,9,22</sup>

During week 6 the nasal pits deepen considerably because of growth of secondary prominences and penetration of the underlying mesenchyme. At first the oronasal membrane separates the pits from the primitive oral cavity by way of newly formed foramina, the primitive choanae (just behind the primary

palate). With the formation of the secondary palate and further development of the primitive nasal chambers, the definitive choanae lie at the junction of the nasal cavity and the pharynx.<sup>8,9,22</sup>

From the 6th week onwards, embryonic anatomy can be assessed by transvaginal 3D sonography.<sup>2,3,6</sup> At 6 weeks, the embryo is characterized by a rounded, bulky head (prominent due to the developing cerebral vesicles – prosencephalon, mesencephalon and rhombencephalon), and a thinner body.



Figs 5A and B: Development of the nasolacrimal groove, 13 weeks fetus and 7 weeks embryo

For 3D visualization of the fetal face, the surface mode is generally used. From weeks 13-14, facial structures have reached an adequate degree of development in order to start studying them for diagnostic purposes.<sup>17</sup> However, images of the fetal face during the first trimester may appear strange to parents and caution is advised while showing those images, so that a distorted mental image of their child is not created, which may affect affective bonds or create inadvertent anxiety. From

18-19 weeks until 35-36 weeks, 3D reconstruction of the fetal face is possible in a high percentage of cases. In our opinion, the most favorable gestational ages for 3D scanning of the fetal face range from weeks 23 until 30. During this period of gestation, we have successfully visualized the face by in a high percentage of the cases, without extending the length of the prenatal 2DUS scan.<sup>10</sup>

**FETAL FACE ANOMALIES**

There is a large number of fetal face anomalies that can be seen using ultrasound techniques. Many of them are often associated with different brain anomalies (Table 1).

3DUS improves and facilitates the identification of fetal face anomalies in planes that cannot be obtained using conventional 2DUS technique. Several authors have reported improved visualization of fetal face and neck in high-risk pregnancies, dysmorphic syndromes due to exposure to teratogens, fetal alcohol syndrome and chromosomal abnormalities.<sup>5,14,24</sup>

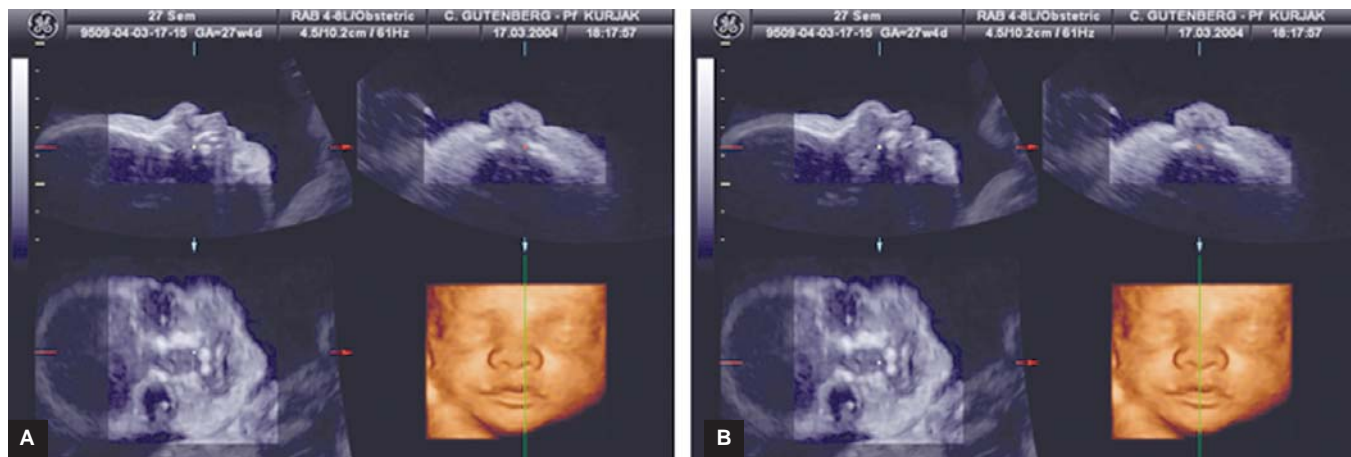
Multiplanar navigation provides valuable modality in the three orthogonal planes for visualization of the fetal face details and reevaluation in recorded volume. Using multiplanar view can be useful in cases of suboptimal fetal position. Ability to navigate through recorded volume using multiplanar view has improved the study of certain morphologic abnormalities (Fig. 6).<sup>25-28</sup> It allows obtaining of true midsagittal plane of the fetal face, important for appropriate evaluation of different facial structures, specially to measure the naso-frontal angle, the assessment of the ocular biometry and the interorbital distance for the diagnosis of the hyper or hypotelorism, or the assessment of the maxilar and mandible in the diagnosis of micrognathia and retrognathia.

**EVALUATION OF MANDIBLE**

The evaluation of the mandible is important because some of anomalies like Pierre Robin syndrome or trisomy 13 and 18 can be associated with mandible anomalies.<sup>29,30</sup> Children born with the mandible anomalies can be at risk of acute neonatal respiratory

**Table 1:** Pathological changes in fetal face structures

<i>Nose Anomalies</i>	<i>Eye Anomalies</i>	<i>Ear Anomalies</i>	<i>Mouth Anomalies</i>	<i>Cranial Anomalies</i>
Arrinia	Hypertelorism	Anotia	Cleft lip/palate	Acrania
Proboscis	Hypotelorism	Microtia	Microstomia	Cranioschisis
lateralis	Anophthalmy	Synotia	Macrostomia	Craniosynostosis
Polirrinia	Monophthalmy	Hypoplastic ear	Aglossia	Scaphocephaly
Nasal cleft	Micropthalmy	Dysplastic ear	Macroglossia	Acrocephaly
Choanal atresia	Cyclopia	Prominent ear	Agnathia	
Nasal tumors:	Cataract	Low-set ears	Micrognathia	Trigonocephaly
Dermoid cyst			Retrognathia	Plagiocephaly
Glioma			Oral tumors:	
Encephalocele			Ranula	
Teratoma			Epignathus	
Broad/Short nasal bridge			Teratoma	



**Figs 6A and B:** 3-dimensional rendering images ensures that true midsagittal plane is used. (A) may seem correct, but reference green line shows that such profile does not belong to the middle line. (B) displays a profile of the face that belongs to a correct midsagittal view

syndrome because the tongue may obstruct the upper airways. There is no strict parallelism between the severity of the anatomical defect and the impairment of respiratory function at birth. That is why is very important the antenatal recognition of even milder cases of mandible anomalies allowing the neonatologist to be present in the delivery room to provide immediate care for the infant and also to prepare everything for the ex-utero intrapartum treatment if needed.<sup>31</sup>

Mandible anomalies are usually diagnosed subjectively as a prominent upper lip and small chin or a subjective impression of a small jaw or posterior displacement of the mandible.<sup>32</sup> Although there have been some attempts to define biometric parameters that would allow objective distinction between normal and abnormal mandibles they do not differentiate retrognathia (abnormal recession of the chin) from micrognathia (insufficient size of the mandible).<sup>16,32,33</sup>

**EAR ANOMALIES**

Fetal ear can be depicted by 3DUS between 9th and 10th week of pregnancy.<sup>3</sup> Some authors have shown that 3DUS is helpful in depicting the morphological detail, location and orientation of the fetal ear (Fig. 7).<sup>34</sup> Accurate depiction of the fetal ear is important because ear anomalies can be associated with complex syndromes. Merz et al concluded that 3DUS consistently depicted facial dysmorphism with greater accuracy and clarity, particularly in cases with subtle facial abnormalities.<sup>5</sup>

**EYE ANOMALIES**

**Ultrasound in Evaluation of Intraorbital Distance**

Hyper or hypotelorism can be evaluated by using the ultrasound technique.

Hypotelorism (Fig. 8), decreased distance between orbits can be present as isolated anomaly but more often it is associated with brain anomalies. Normal intraorbital distance is present when between the orbits there is just enough space for one more orbit. That distance is bigger in hypertelorism (Fig. 9), which can be easily depicted by using ultrasound and can be associated with different syndromes such as Crouzon, Down or Turner.<sup>35</sup>

Cyclopia (presence of the one eye in the middle of the forehead) and synophthalmia are different levels of partial or total eye conjunction as a consequence degradation of the brain tissue in the middle of the skull between 19th and 21th day of pregnancy. Different brain anomalies, like holoprosencephaly can be accompanying cyclopia.

**EYE MOVEMENTS**

Organization of fetal eye movements begins in the second trimester. First movements that can be observed are sporadic movements of restricted frequency around 16th to 18th week of pregnancy.<sup>36</sup> Around week 24 to 26 they appear more often and start to consolidate, changing the periods with eye movement and periods when eye movement cannot be observed. Through next 10 weeks mechanism for maintenance of that rhythm matures and around 37 and 38 weeks of pregnancy constant values of eye movements (REM) and no eye movements (NEM) appear. In that period REM phase lasts between 27 and 29 minutes and NEM phase 23 to 24 minutes, similar to the values in the newborn.<sup>37</sup> Incidence of eye movements is gradually increasing from 20th to 36th week of pregnancy (Fig. 10). From 35 to 38th week eye movements integrate with other functions (heart action, fetal movements into well-organized behavior patterns).<sup>38,39</sup>

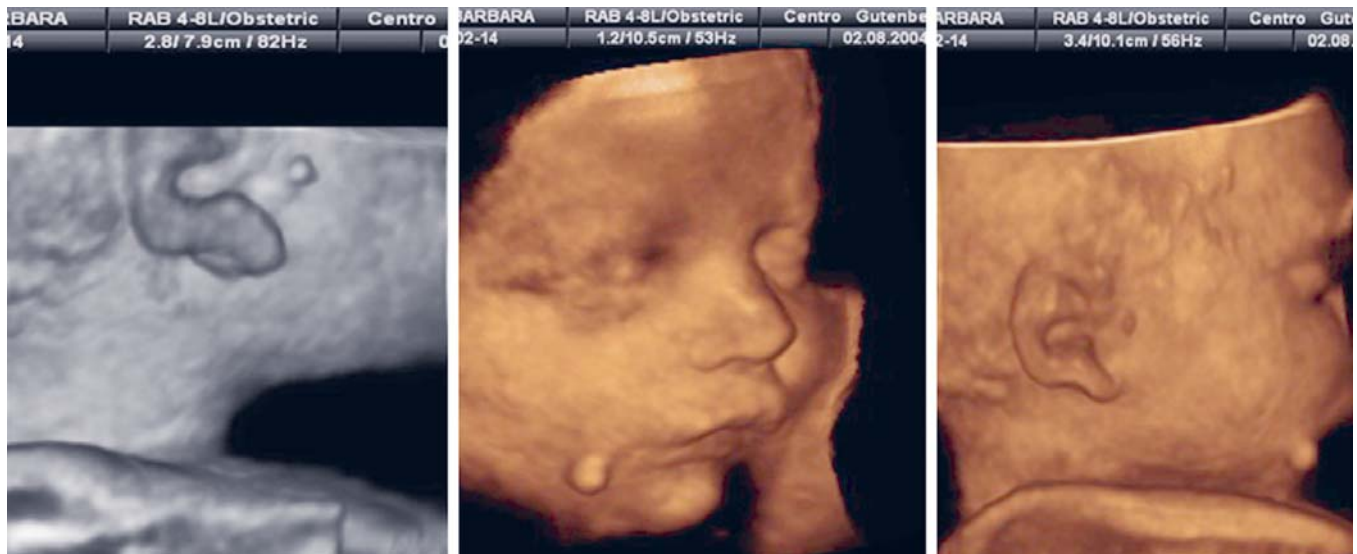

Fig. 7: Display of ear and face appendix

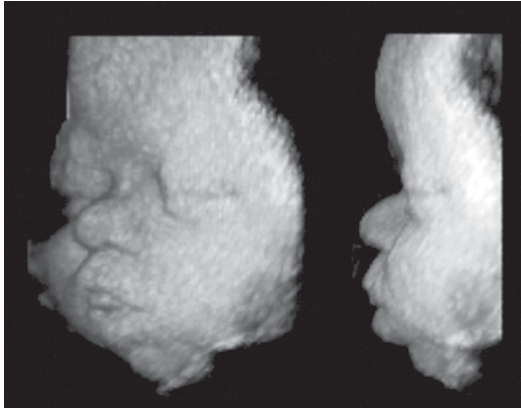


Fig. 8: Hypotelorism

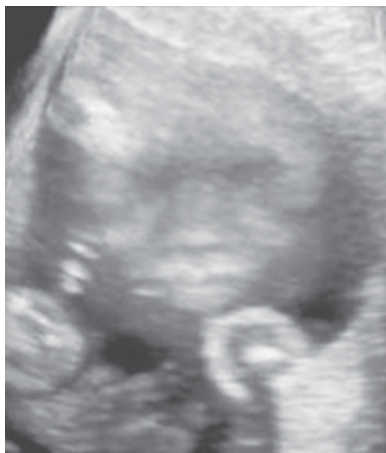

Fig. 9: Hypertelorism

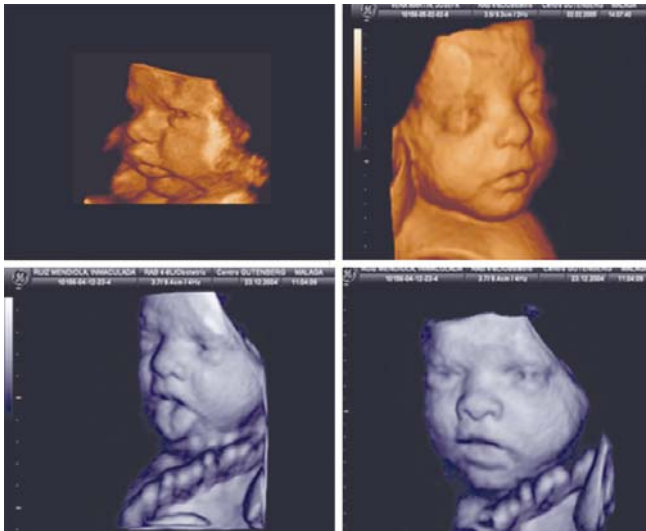

Fig. 10: Demonstration of open eyelids in the second half of the pregnancy

### FETAL BONY STRUCTURES

Fetal head bones can be visualized using surface rendering or transparent maximum (Fig. 11). The threshold level can also be modified to enable visualization of facial surface as well as bones. Abnormal development of the sutures can be associated with dysmorphic syndromes and metabolic disturbances.<sup>7,34,40</sup> With 3DUS visualization of overlapping sutures in fetal death and in craniosynostosis or abnormal cranial contours such as cloverleaf skull can be clearly seen.<sup>25</sup> This possibility is also very helpful in the evaluation of nasal bones as described by several authors.<sup>7,41-43</sup>

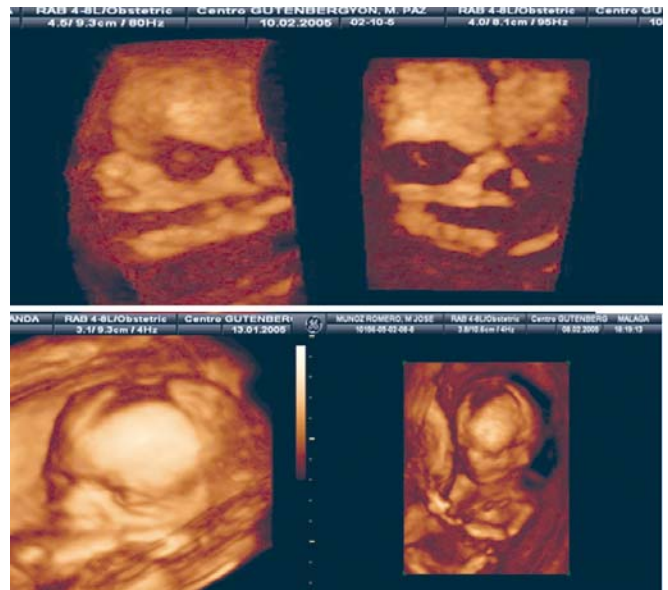
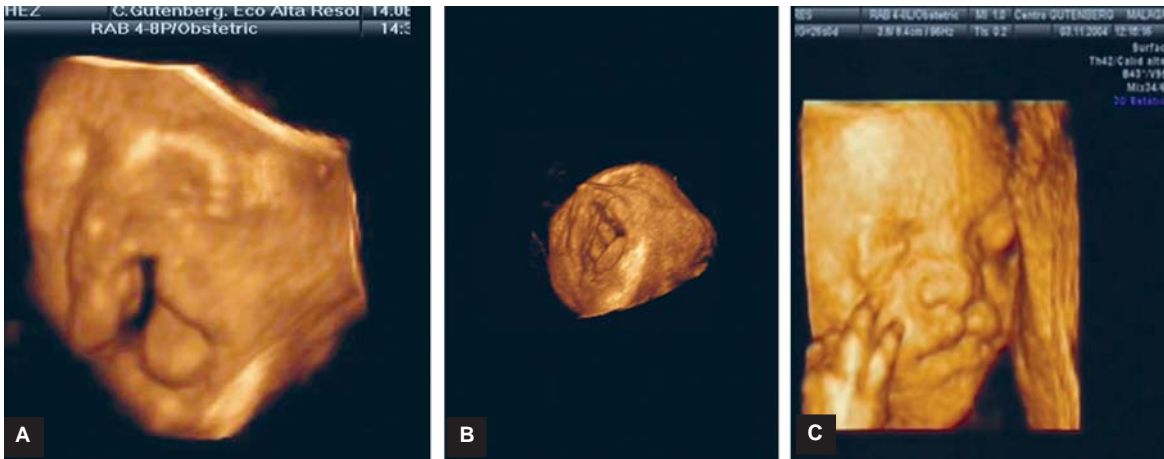


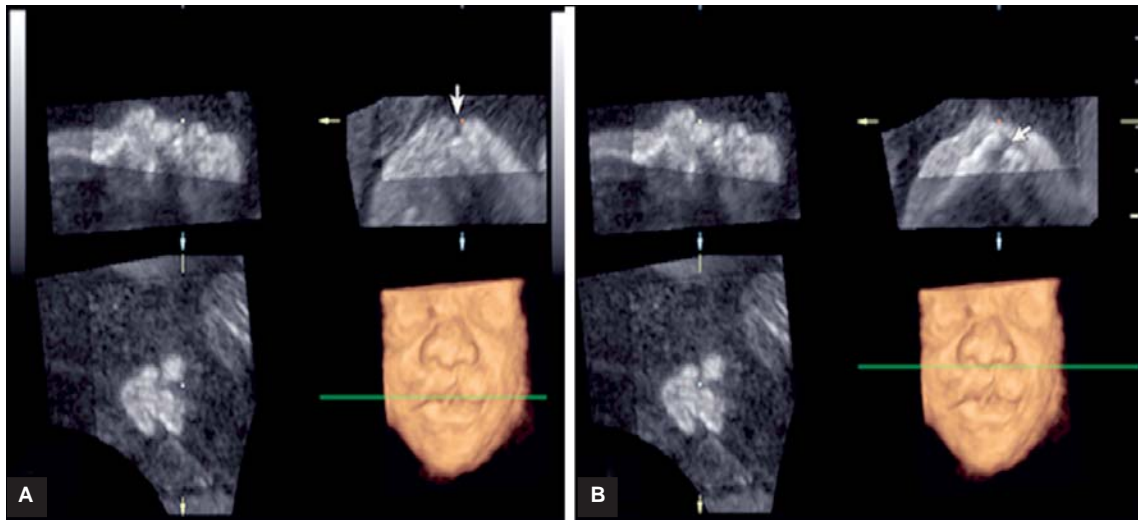
Fig. 11: 3D image of fetal face bony structures—using transparent maximum and surface rendering mode

Cleft lip and palate, as the most common craniofacial malformation, can be diagnosed using both 2 and 3DUS<sup>16</sup> (Figs 12 and 13). In a study carried out by Johnson and Pretorius they found that 3DUS has an impact on diagnosis and clinical management, detecting the associated cleft palate much more often than 2DUS.<sup>44</sup> Multiplanar images help to establish the location and extension of the anomaly. The surface rendering mode, apart from being a reference for the multiplanar navigation also allows to obtain images easy to comprehend, helping the parents as well as the practitioners to make decisions.<sup>16</sup>

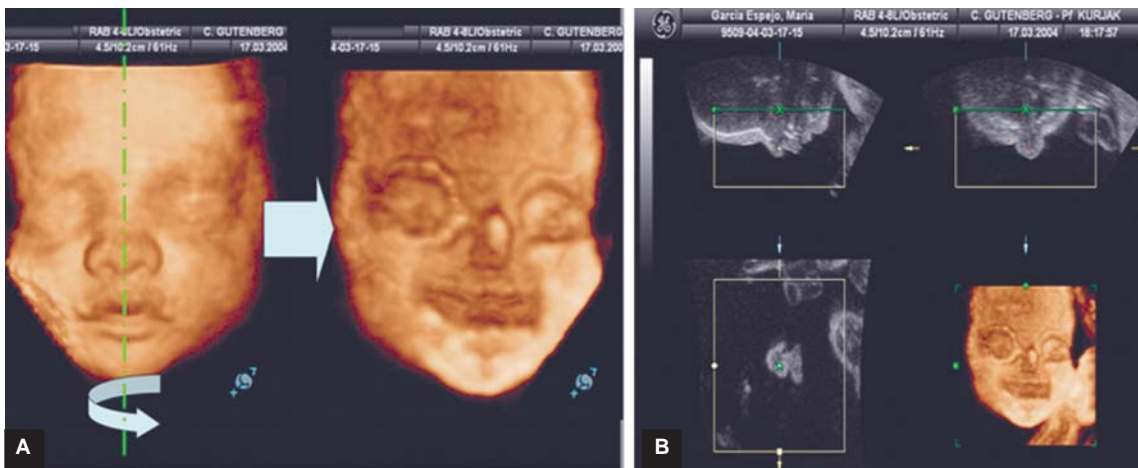
Another interesting possibility is to rotate the surface rendered through 180° on the vertical axis to obtain the called by Campbell and co-workers “3D Reverse Face View” (Fig. 14). These authors published two years ago interesting results with this approach in the antenatal categorization of facial clefting and in particular clefting of the hard palate. In 2005 they have reported again improvement in the cleft palate categorization using this technique.<sup>45,46</sup>



Figs 12A to C: Cleft lip and palate, 3D display



Figs 13A and B: Detection of small cleft lip by multiplanar imaging



Figs 14A and B: Campbell's "3D reverse face view"

## FACIAL NERVE PARESIS

One of the usage of 4DUS can be in evaluation of the presence of the facial nerve palsy. The criterion for the diagnosis is asymmetrical facial movement and detection of the movements limited to only one side of the face. Unfortunately, during the relaxed phase it is not possible to evaluate the status of the facial nerve. Therefore, during the active phase, the fetus should be scanned by 4DUS.<sup>7</sup>

Also, the origin of the facial expression can be external and before the final diagnosis, the sonographer should be aware of this pitfall. For example, force of the fetal hand can alter the facial expression on one side of the face, causing asymmetry. This kind of asymmetry, however, should be differentiated from pathological features such as unilateral facial palsy.<sup>4,16</sup>

## FUNCTIONAL STUDY OF FETAL FACIAL EXPRESSION

4DUS has additional advantages in studying fetal activity in the surface rendered mode and is particularly superior for fast fetal movements.<sup>17</sup> With 2DUS, fetal movements such as yawning, swallowing and eyelid movements cannot be displayed simultaneously while with 4DUS, the simultaneous facial movements can be clearly depicted.<sup>43</sup>

The qualitative and quantitative aspects of behavioral patterns expand rapidly as the pregnancy progresses, and the random movements of the fetal body, which are the earliest signs of fetal activity, change into the well-organized behavioral patterns, observed later in gestation. Analysis of the dynamics of fetal behavior has led to the conclusion that fetal behavioral patterns directly reflect developmental and maturational processes of the fetal central nervous system. With 4D sonography it is now possible to produce measurable parameters for the assessment of normal neurobehavioral development.<sup>54-56</sup>

There are several types of jaw movement patterns such as isolated jaw movement, sucking and swallowing, which can be observed by 2DUS.<sup>17</sup> The possibility of observing facial expressions in detail may be of both scientific and diagnostic value, opening up an entire new field of investigation with many unanswered questions.<sup>47,48</sup> Two examples of questions that remain to be answered are: (1) when do facial expressions start; and (2) which facial expression predominates in fetal life and at what gestational age it can be first observed (Figs 15A to F)?

2DUS and 4DUS are complementary methods used for the evaluation of fetal movements. However, the quality of each fetal movement can be visualized and evaluated more precisely by 4DUS.<sup>15</sup> Fetal behavioral patterns in the third trimester between 30th and 33rd weeks of gestation and the continuity between fetal and neonatal behavior have been recently evaluated.<sup>12,51</sup>

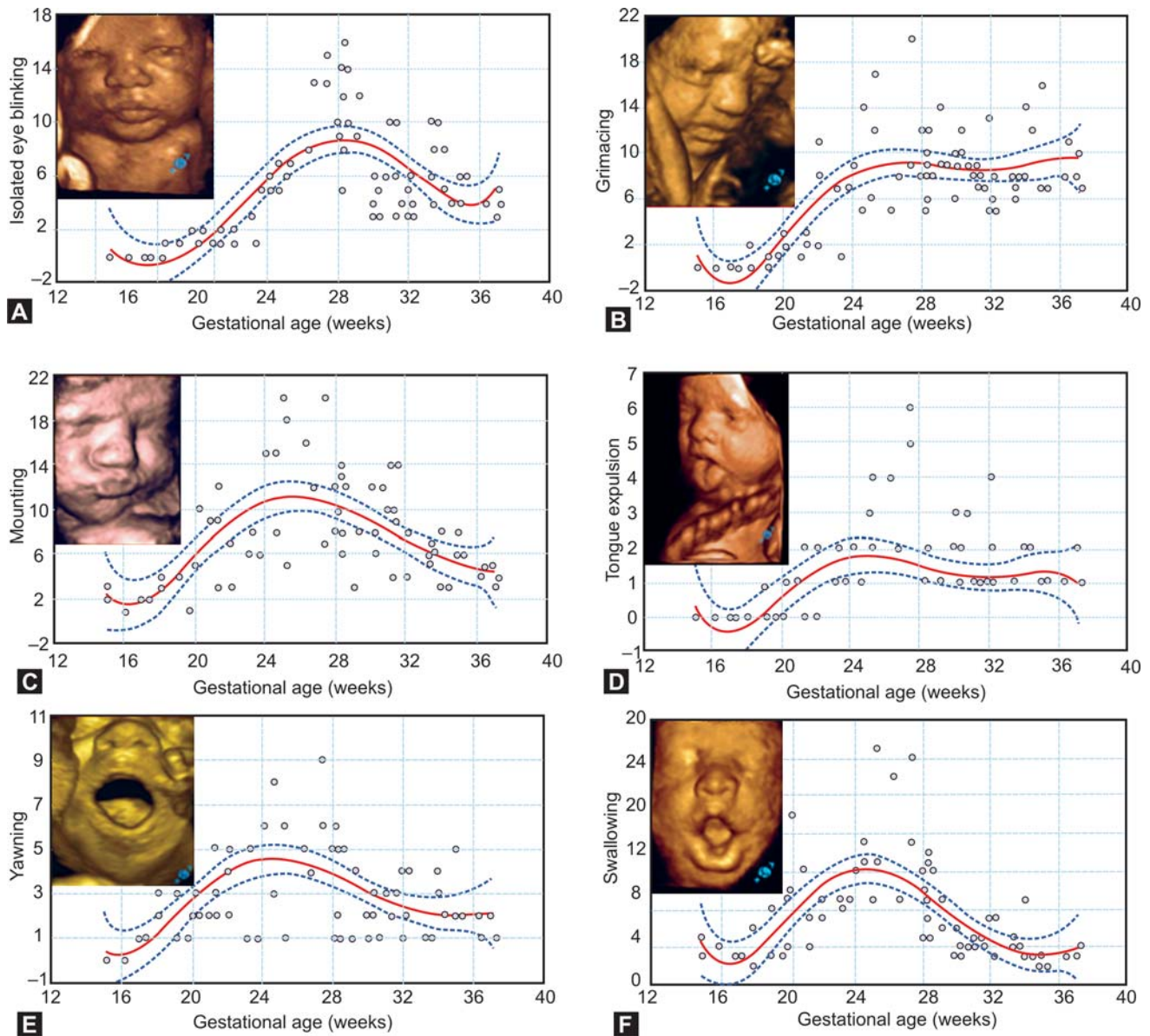
In the second and third trimesters, all facial movements can be visualized by 4DUS (Fig. 16). Furthermore, 4DUS opened, for the first time, the possibility of visualizing the full range of facial expressions, including subtle grimaces, similar to emotional expressions in adults.<sup>14</sup> The most frequent facial movement patterns in the second trimester were isolated eye blinking, grimacing, suckling and swallowing, whereas mouthing, yawning, tongue expulsion and smiling could be seen less frequently (Fig. 17).<sup>7,14</sup> We noted a tendency towards decreased frequency of observed facial expressions with increasing gestational age. At the beginning of the second trimester, the fetuses began to display a tendency towards increased frequency of observed fetal facial expression to the end of second trimester. All types of facial expression patterns display the peak frequency at the end of second trimester, except in isolated eye blinking which began to increase at the beginning of 24 weeks of gestation because the fetuses cannot open the eyelids before this period. During the third trimester, the fetuses began to display decreasing incidence or paucity of fetal facial expression.<sup>14</sup>

The systematic investigations of fetal facial expressions confirmed that all components of the fetal yawning pattern, prolonged jaw opening followed by a quick closure and accompanied by head flexion and elevation of arms, can easily be recognized by 4DUS in this period.<sup>50</sup> Furthermore, when the fetal yawning in the third trimester was compared with the yawning in the neonates during the first week of life, no differences were found in the frequencies of this reflex. The frequency of yawning gradually increased between 15th and 24th week when a short plateau was observed from 24th to 26th week and was followed by a slight decrease towards the term.<sup>14</sup> A clear gestational age-related trend in the frequency of yawning could be interpreted as the maturation of the brain stem and possibly the acquisition of control of more cranial structures over yawning pattern. These findings have provided new information about the course of neurodevelopment of this interesting, but poorly understood reflex. Whether this is altered in cases of neurodevelopmental disturbances and whether such alterations can give us insight into the function of fetal nervous system in high risk pregnancies, remains to be determined.<sup>7</sup>

Fetal yawning is still quite a mysterious phenomenon, and its possible relation to the pathological conditions, particularly those affecting fetal central nervous system has not been investigated so far, despite the clearly altered incidence of yawning in a wide spectrum of CNS disorders, observed in adults. The early reports of yawning movements in the 20 weeks old fetus indicated that 4DUS might facilitate the investigation of this infrequent movement pattern.<sup>50</sup>

This impressive finding, however, raises a number of questions, many of which are yet to be answered. First, precise criteria to distinguish between these facial expressions in the

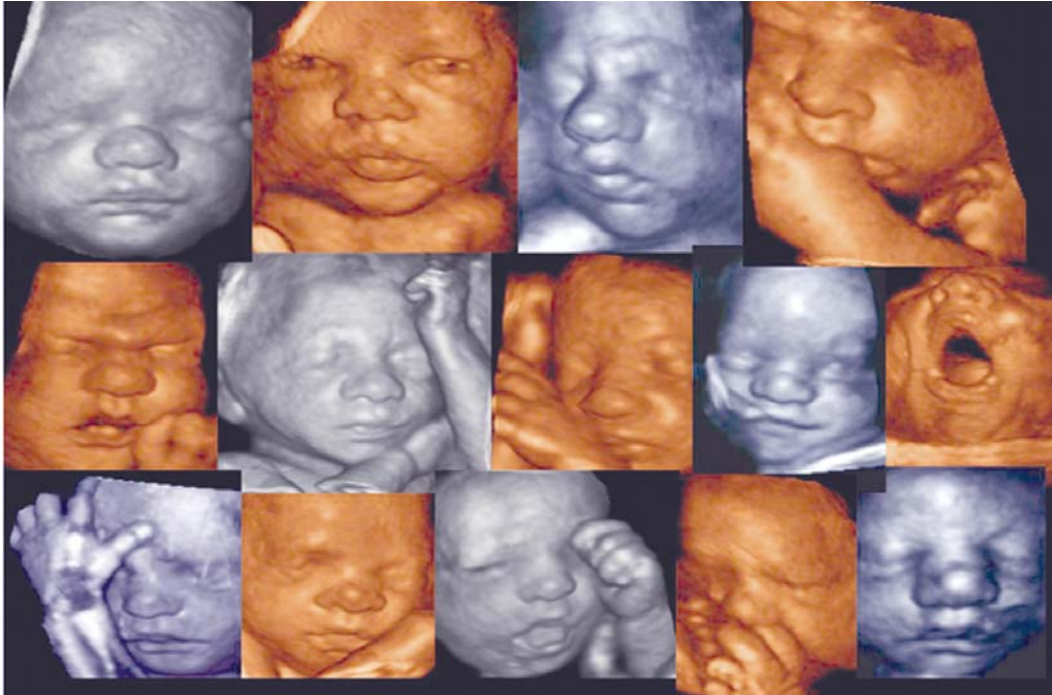



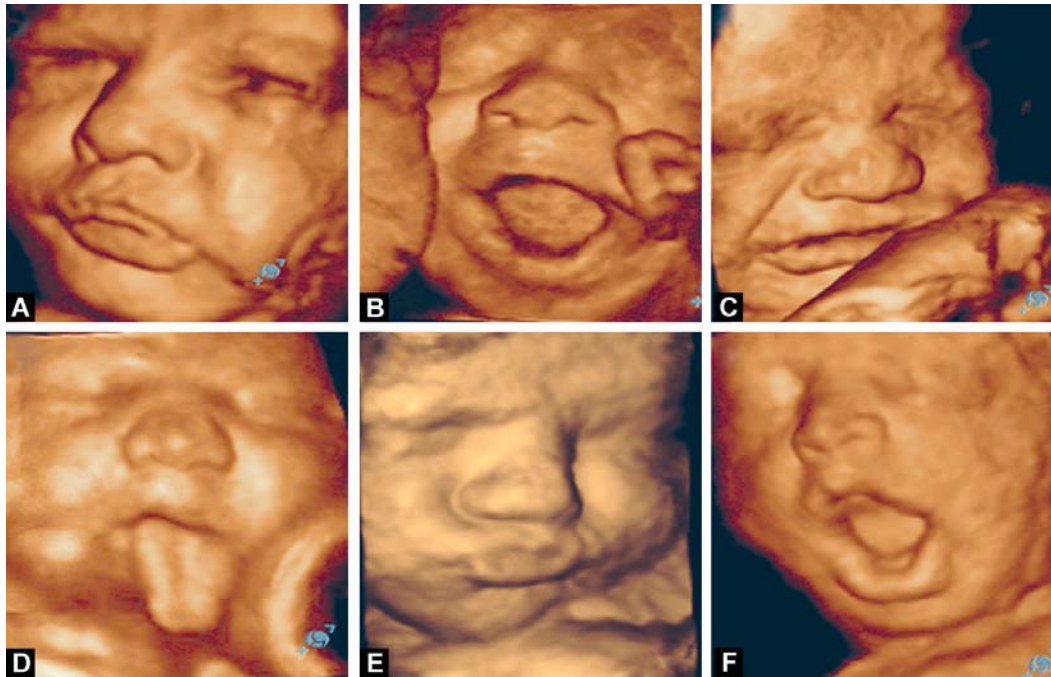
**Figs 15A to F:** Frequency of observed facial expressions versus gestational age

fetus should be established. The exact onset of facial expressions has not been determined and it is still unclear whether their appearance is gestational age related. The maturation of midbrain also begins in the second trimester. It consists of the dopamine-producing substantia nigra, the inferior-auditory and superior-visual colliculus, and cranial nerves III–IV, which together with the medial longitudinal fasciculus and the VI cranial nerve, control eye movements.<sup>31</sup> This explains the delayed onset of eye movements, which cannot be registered before 16th postconceptional week. The maturation of the medulla oblongata is also revealed by the appearance of the breathing movements as well as the swallowing, hiccups,

yawning and jaw opening, visible between 9th and 11th week.<sup>31</sup> Facial movements, which are also controlled by V and VII cranial nerve, appear around 10–11 weeks, while delayed onset of more specific functions, such as the selective response to sounds and vibration, can be explained by the prolonged pontine maturation. The nuclei of the facial nerve, a structure that controls these motor patterns, are developed by the end of first trimester, indicating that some facial grimaces could appear rather early in gestation.<sup>32,8</sup> The possibility of studying such subtle movements certainly opens a completely new area of investigation. One potential value of such observations could be the detection of facial nerve paresis *in utero*. It remains to



**Fig. 16:** Various displays of fetal face movements in the second half of the pregnancy



**Fig. 17:** Illustration of different facial expressions that can be studied: isolated eye blinking, yawning, grimacing, tongue expulsion, mouthing and swallowing

be determined to what extent are the facial motoric patterns related to the function and integrity of the CNS. Nevertheless, the fact that even in the embryonic period, the same inductive forces that cause growth and reshaping of the neural tube influence the development of facial structures, and that many genetic disorders affecting the CNS are also characterized by dysmorphology and dysfunction of facial structures, emphasize the importance of these investigations. Obviously, the story of fetal intrauterine activity is far from being complete; the development of new recording techniques should enrich the perspective of intrauterine life.

**FETAL FACE MOVEMENTS IN HIGH RISK PREGNANCIES**

De Vries has analyzed the literature about fetuses which were in high risk group for movement anomalies.<sup>51</sup> The study has shown that fetal movement activity can be changed both qualitatively or quantitatively depending on the anomaly. They have also pointed some risk factors which can lead to complications accompanied by changes in fetal movements. Risk does not mean by all means that the problem will appear, but it alerts on additional caution. The advantage of that study was that both mother and the fetus were considered. Healthy mother can develop problems during the pregnancy, and, on the contrary, the pregnancy can pass well although medical or obstetrical history is present.<sup>52</sup>

Ahmed and co-workers have analyzed fetal behavior patterns in 8 high-risk fetuses using 4D ultrasound (Table 2).<sup>53</sup> Together with changes in other body movements, changes in

**Table 2:** Classification of fetal face movements based on 3D/4D ultrasound

Yawning	Movement very similar to postnatal yawning. Prolonged wide opening of the jaws followed by quick closure, with retroflexion of the head and elevation of arms. This movement pattern is non-repetitive.
Swallowing	Indicates that the fetus is drinking amniotic fluid. Swallowing consists of displacements of tongue and/or larynx. It develops before sucking.
Sucking	Very frequent pattern of fetal behavior including regular jaw opening and closing and lasting one second. Sucking of the thumb or other fingers can be visualized.
Smiling	It consists of elevation of the mouth angles.
Tongue expulsion	Facial expression characterized by expulsion of the tongue.
Grimacing	The wrinkling of the brows or face in frowning.
Mouthing	A facial expression characterized by mouth manipulation to investigate an object. Mouthing is the most common in fetus and it may develop into a persistent, stereotyped behavior pattern.
Eye blinking	A reflex that closes and opens eyes rapidly. Brief closing of eyelids by involuntary normal periodic closing, as a protective measure, or by voluntary action.

fetal face movements were present. In the anencephalic fetus all behavioral patterns were decreased comparing to normal parameters through all three trimesters. They have observed no face movements in the second and third trimester. In fetus with diaphragmal hernia all face movements were normal. In fetus with Meckel-Gruber’s syndrome reduced frequency of mouthing, grimacing and swallowing was observed.<sup>53</sup>

**CONCLUSION**

The evaluation of the fetal face is an important part of every ultrasound examination since detailed facial examination can provide many information alerting the examiner about possible associated anomalies. Face and the brain have the same embryonic origin. By using 2 and 3D ultrasound techniques, it is possible to obtain clear images of different fetal face defects. Incorporation of the 4D ultrasonography made it possible to examine fetal behavior including fetal face movements. In that way using the ultrasound in the examination of the fetal face provides many new information not just about the morphology but also about neurological development and function of the fetal face.

**REFERENCES**

1. De Meyer V, Zeman W, Palmer CC. The face predicts the brain: diagnostic significance of medial facial anomalies for holoprosencephaly (archiencephaly). *Pediatrics* 1964;34: 256-58.
2. Andonotopo W, Medic M, Salihagic-Kadic A, Milenkovic D, Maiz N, Scazzocchio E. The assessment of fetal behaviour in early pregnancy: comparison between 2D and 4D sonographic scanning. *J Perinat Med* 2005;33:406-14.
3. Kurjak A, Pooh RK, Merce LT, Carrera JM, Salihagic-Kadic A, Andonotopo W. Structural and functional early human development assessed by three-dimensional and four-dimensional sonography. *Fertil Steril* 2005;84:1285-99.
4. Azumendi G, Kurjak A, Andonotopo W, Herman M. 2D Sonography in the evaluation of normal and abnormal fetal face. *U:Donald School Atlas of Fetal Anomalies*. New Delhi:Jaypee Brothers Medical Publishers Ltd 2007:111-41.
5. Merz E, Weber G, Bahlmann F, Miric- Tesanic D. Application of transvaginal and abdominal three-dimensional ultrasound for the detection or exclusion of malformations of the fetal face. *Ultrasound Obstet Gynecol* 1997; 9:237-43.
6. Kurjak A, Veccek N, Hafner T, Bozek T, Funduk Kurjak B, Ujevic B. Prenatal diagnosis: what does four dimensional ultrasound add. *J Perinat Med* 2002;30:57-62.
7. Kurjak A, Azumendi G, Andonotopo W, Salihagic-Kadic A. Three- and four-dimensional ultrasonography for the structural and functional evaluation of the fetal face. *Am J Obstet Gynecol* 2007;196:16-28.
8. Evans DJ, Francis-West PH. Craniofacial development: making faces. *J Anat* 2005;207:435-36.
9. Nuckolls GH, Shum L, Slavkin HC. Progress toward understanding craniofacial malformations. *Cleft Palate Craniofac J* 1999; 36:12-26.

10. Azumendi G, Kurjak A: Three-dimensional and four-dimensional sonography in the study of the fetal face. *Ultrasound Rev Obstet Gynecol* 2003;3:160-69.
11. Kurjak A, Azumendi G, Veccek N, Kupesic S, Solak M, Varga D, et al. Fetal hand movements and facial expression in normal pregnancy studied by four-dimensional sonography. *J Perinat Med* 2003;31:496-508.
12. Kurjak A, Stanojevic M, Andonotopo W, Salihagic-Kadic A, Carrera JM, Azumendi G. Behavioural pattern continuity from prenatal to postnatal life—a study by four-dimensional (4D) ultrasonography. *J Perinat Med* 2004;32:346-53.
13. Andonotopo W, Kurjak A, Kosuta MI. Behaviour of an anencephalic fetus studied by 4D sonography. *J Matern Fetal Neonatal Med* 2005;17:165-68.
14. Kurjak A, Andonotopo W, Hafner T, Salihagic-Kadic A, Stanojevic M, Azumendi G, et al. Normal standards for fetal neurobehavioural developments – longitudinal quantification by four-dimensional sonography. *J Perinat Med* 2006;34:56-65.
15. Nelson TR, Downey DB, Pretorius DH, Fenster A, (eds) *Three-Dimensional Ultrasound*. Philadelphia, PA: Lippincott Williams & Wilkins; 1999:11-32.
16. Azumendi G, Kurjak A, Comas Gabriel C. 3D sonography in the study of the fetal face. U:Kurjak A, Azumendi G. *The fetus in three dimensions*. London: Informa UK Ltd, 2007:181-215.
17. Lee A. Four-dimensional ultrasound in prenatal diagnosis; leading edge in imaging technology. *Ultrasound Rev Obstet Gynecol* 2001;1:194-98.
18. Yan F, Dai SY, Akther N, Kuno A, Yanagihara T, Hata T. Four-dimensional sonographic assessment of fetal facial expression early in the third trimester. *Int J Gynaecol Obstet* 2006;94:108-13.
19. Kurjak A, Miskovic B, Stanojevic M, Amiel-Tison C, Ahmed B, Azumendi G, Vasilj O, Andonotopo W, Turudic T, Salihagic-Kadic A. New scoring system for fetal neurobehavior assessed by three- and four-dimensional sonography. *J Perinat Med* 2008;36:73-81.
20. Precht HFR. Ultrasound studies of human fetal behaviour. *Early hum Dev* 1985;12:91-98.
21. Evans DJ, Francis-West PH. Craniofacial development: making face. *J Anat* 2005;207:435-36.
22. Rice DP. Craniofacial anomalies: from development to molecular pathogenesis. *Curr Mol Med* 2005;5:699-722.
23. Stoll C, Clementi M. Prenatal diagnosis of dysmorphic syndromes by routine fetal ultrasound examination across Europe. *Ultrasound Obstet Gynecol* 2003;21:543-51.
24. Matthews L, Marais AS, Kay HH, Viljoen DL. Possible ultrasound markers for fetal alcohol syndrome: assessment of the fetal face and brain. *Ultrasound Obstet Gynecol* 2004;24:264.
25. Gonçalves LF, Lee W, Espinoza J, Romero R. Three- and four-dimensional ultrasound in obstetric practice: does It Help? *J Ultrasound Med* 2005; 24:1599-624.
26. Chen ML, Chang CH, Yu CH, Cheng YC, Chang FM. Prenatal diagnosis of cleft palate by three-dimensional ultrasound. *Ultrasound Med Biol* 2001;27:1017-23.
27. Chmait R, Pretorius D, Jones M, Hull A, James G, Nelson T, et al. Prenatal evaluation of facial clefts with two-dimensional and adjunctive three-dimensional ultrasonography: a prospective trial. *Am J Obstet Gynecol* 2002;187:946-49.
28. Ulm MR, Kratochwil A, Ulm B, Lee A, Bettelheim D, Bernaschek G. Three-dimensional ultrasonographic imaging of fetal tooth buds for characterization of facial clefts. *Early Hum Dev* 1999;55:67-75.
29. Rotten D, Levaillant JM, Martinez H, Docou le Pointe H, Vicaut E. The fetal mandible: a 2D diagnosis of retrognathia and micrognathia. *Ultrasound Obstet Gynecol* 2002;19:122-30.
30. Nicolaidis CM, Selvesen DR, Snijders RJM, Gosden CM. Fetal facial defects associated malformations and chromosomal abnormalities. *Fetal Diagn Ther* 1993;8:1-9.
31. Salihagic-Kadic A, Kurjak A, Medic M, Andonotopo W, Azumendi G. New data about embryonic and fetal neurodevelopment and behavior obtained by 3D and 4D sonography. *J Perinat Med* 2005;33:478-90.
32. Otto C, Platt LD. The fetal mandible measurement: and objective determination of fetal jaw size.. *Ultrasound Obstet Gynecol*. 1991;1: 12-17.
33. Lee W, Kirk JS, Shaheen KW, Romero R, Hodges AN, Comstock CH. Fetal cleft lip and palate detection by three-dimensional ultrasonography. *Ultrasound Obstet Gynecol* 2000; 16:314-20.
34. Shih JC, Shyu MK, Lee CN, Wu CH, Lin GJ, Hsieh FJ. Antenatal depiction of the fetal ear with three-dimensional ultrasonography. *Obstet Gynecol* 1998;91:500-05.
35. Lausin I, Kurjak A, Miskovic B, Stanojevic M. Four dimensional ultrasound in the assessment of structure and movement of the fetal face. *Gynecol Perinatol* 2008;17:83-93.
36. Awoust J, Levi S. Neurological maturation of the human fetus. *Ultrasound Med Biol* 1983;9:583-87.
37. Inoue M, Koyanagi T, Nakahara H. Functional development of human eye-movement in utero assted quantitatively with real time ultrasound. *Am J Obsete Gynecol* 1986:155:256-63.
38. Parmelee AH, Stern E. Development of states in infants. U: Clemente CD, Purpura DP, Mayer FE. *Sleep and the maturing central nervous system*. New York: Academic Press, 1972: 100-215.
39. Kurjak A, Carrera J, Medic M, Azumendi G, Andonotopo W, Stanojevic M. The antenatal development of fetal behavioral patterns assessed by four-dimensional sonography. *J Matern Fetal Neonatal Med* 2005;17:401-16.
40. Pretorius DH, Nelson TR, Three-dimensional ultrasound. *J Ultrasound Med* 1994;13:871-76.
41. Peralta CF, Falcon O, Wegrzyn P, Faro C, Nicolaidis KH. Assessment of the gap between the fetal nasal bones at 11 to 13 + 6 weeks of gestation by three-dimensional ultrasound. *Ultrasound Obstet Gynecol* 2005;25:464-67.
42. Rembouskos G, Cicero S, Longo D, Vandecruys H, Nicolaidis K. Assersment of the fetal nasal bone at 11-14 weeks' gestation by three-dimensional ultrasound. *Ultrasound Obstet Gynecol* 2004; 23:232-36.
43. Kozuma S, Baba K, Okai T, Taketani. Y. Dynamic observation of the fetal face by three-dimensional ultrasound. *Ultrasound Obstet Gynecol* 1999;13:283-84.
44. Johnson DD, Pretorius DH, Budorick NE, Jones MC, Lou KV, James GM, Nelson TR. Fetal lip and primary palate: three-dimensional versus two-dimensional US. *Radiology* 2000; Oct;217(1):236-39.
45. Abuhamad A. Automated multiplanar imaging: a novel approach to ultrasonography. *J Ultrasound Med* 2004; 23:573-76.

46. Campbell S, Lees CC. The three-dimensional reverse face (3D RF) view for the diagnosis of cleft palate. *Ultrasound Obstet Gynecol* 2003; 22:552-54.
47. Hata T, Kanenishi K, Akiyama M, Tanaka H, Kimura K Real-time 3-D sonographic observation of fetal facial expression. *J Obstet Gynaecol Res* 2005;31:337-40.
48. Kuno A, Akiyama M, Yamashiro C, Tanaka H, Yamagihara T, Hata T. Three-dimensional sonographic assessment of fetal behaviour in the early second trimester of pregnancy. *J Ultrasound Med* 2001;20:1271-75.
49. Kurjak A, Stanojevic M, Azumendi G, Carrera JM. The potential of four-dimensional (4D) ultrasonography in the assessment of fetal awareness. *J Perinat Med* 2005;33:46-53.
50. Walusinski O, Kurjak A, Andonotopo W, Azumendi G. Fetal yawning assessed by 3D and 4D sonography. *Ultrasound Rev Obstet Gynecol* 2005;5:210-17.
51. de Vries JI, Fong BF. Changes in fetal motility as a result of congenital disorders: an overview. *Ultrasound Obstet Gynecol* 2007;29:590-99.
52. Roodenburg PJ, Wladimiroff JW, van Es A, Prechtl HF. Classification and quantitative aspects of fetal movements during second half of normal pregnancy. *Early Hum Dev* 1991;25:19-35.
53. Ahmed B, Kurjak A, Andonotopo W, Khenyab N, Saleh N, Al-Mansoori Z. Fetal behavioral and structural abnormalities in high risk fetuses assessed by 4D sonography. *The Ultrasound Review of Obstetrics and Gynecology* 2005;5:1-13.
54. Steiner H, Staudach A, Spitzer D, Schaffer H. Three-dimensional ultrasound in obstetrics and gynaecology: technique, possibilities and limitations. *Hum Reprod* 1994;9:1773-78.
55. Maier B, Steiner H, Wienerroither H, Staudach A. The psychological impact of three-dimensional fetal imaging on the fetomaternal relationship. In: Baba K, Jurkovic D (Eds): *Three-Dimensional Ultrasound in Obstetrics and Gynecology*. New York: Parthenon, 1997:67-74.
56. Rustico MA, Mastromatteo C, Grigio M, Maggioni C, Gregori D, Nicolini U. Two-dimensional vs. two- plus four-dimensional ultrasound in pregnancy and the effect on maternal emotional status: a randomized study. *Ultrasound Obstet Gynecol* 2005; 25:468-72.