

1989–2019: 30 Years of 3D Ultrasound in Obstetrics and Gynecology

¹Eberhard Merz, ²Asim Kurjak

ABSTRACT

Three-dimensional (3D)/four-dimensional (4D) ultrasound has profited greatly from the developments in computer and 3D probe technology. It has become such a sophisticated technique in the fields of prenatal diagnosis, gynecology, and breast diagnosis that it is indispensable for the skilled ultrasound operator. It represents a problem-solving tool in different circumstances, not only in the demonstration of pathological findings, but also in the verification of normal findings. This is particularly important in obstetrics in patients with an increased risk for a specific fetal malformation. In such a situation, the parents-to-be can easily be reassured by being shown the normal fetal anatomy. On the contrary, with the ability to demonstrate the fetus to the parents-to-be as in a photograph, there may be a risk that they believe 3D ultrasound to be able to detect any possible defect and can thus guarantee the “perfect baby.” However, this would definitively be the wrong conclusion.

Keywords: Four-dimensional ultrasound, HDlive mode, Silhouette mode, Three-dimensional ultrasound.

How to cite this article: Merz E, Kurjak A. 1989–2019: 30 Years of 3D Ultrasound in Obstetrics and Gynecology. *Donald School J Ultrasound Obstet Gynecol* 2018;12(2):94-98.

Source of support: Nil

Conflict of interest: None

INTRODUCTION

Thirty years of 3D ultrasound in obstetrics and gynecology represents an extraordinary success story in recent ultrasound history. However, as with many new technologies, the beginning was anything but easy. Even though initial experimental *in vitro* ultrasound studies had already been published by 1974,¹ the clinical application of 3D ultrasound only started several years later with the first commercial 3D ultrasound unit (Combison 330) launched by Kretztechnik, Zipf, Austria, in 1989.^{2,3} This system was already equipped with special 3D

transducers that enabled automatic and precise volume acquisition, making it possible for the first time to display the three orthogonal two-dimensional (2D) image planes at the same time on the monitor (multiplanar or triplanar display).^{3,4} Nevertheless, not a few experienced 2D ultrasound operators were initially skeptical regarding the clinical use of this new technique and viewed 3D ultrasound as a difficult, inconvenient, and even unnecessary method.⁵ A turnaround occurred with the First World Congress on 3D Ultrasound in Obstetrics and Gynecology from September 5 to 6, 1997 in Mainz, Germany (Fig. 1),³ and with the Second World Congress on 3D Ultrasound in Obstetrics and Gynecology from October 14 to 15, 1999 in Las Vegas, United States (Fig. 1).

A growing interest in the new technology, as well as factors, such as an increase in 3D publications, the development of new display modes, the simplification of the operation process, faster rendering due to greater computer processing power, in addition to the improvement of image quality, and the decrease in costs further contributed to this development and led to the global application of the technology. However, for economic reasons worldwide, only national 3D conferences and courses followed (Fig. 2), and until now, no further World Congresses have been organized.

Due to the rapidly evolving developments in 3D/4D ultrasound over the past few years, the need to organize a third World Congress on 3D Ultrasound in Obstetrics and Gynecology became apparent. Asim Kurjak and I therefore, decided to organize such a congress in Dubrovnik, Croatia in 2019.

The tremendous progress made in 3D ultrasound over the past 30 years has shown it to be not only a valuable supplementary method to conventional 2D ultrasound, but confirmed it as being essential for the precise demonstration of suspicious findings. In comparison with 2D ultrasound, 3D sonography provides the operator with a number of advantages: Several visualization modes, precise control of a certain anatomical plane, digital long-term storage of the volumes, and the possibility of performing virtual ultrasound examinations.³⁻⁶

In prenatal diagnosis, 3D ultrasound provides the operator with excellent multiplanar, surface, and transparent images of the embryo and the fetus, allowing the precise demonstration of a normal anatomy and

¹Professor, ²Professor Emeritus

¹Center for Ultrasound and Prenatal Medicine, Frankfurt am Main, Germany

²Department of Obstetrics and Gynecology, School of Medicine University of Zagreb, Zagreb, Croatia

Corresponding Author: Eberhard Merz, Professor, Center for Ultrasound and Prenatal Medicine, Frankfurt am Main, Germany e-mail: merz.eberhard@web.de


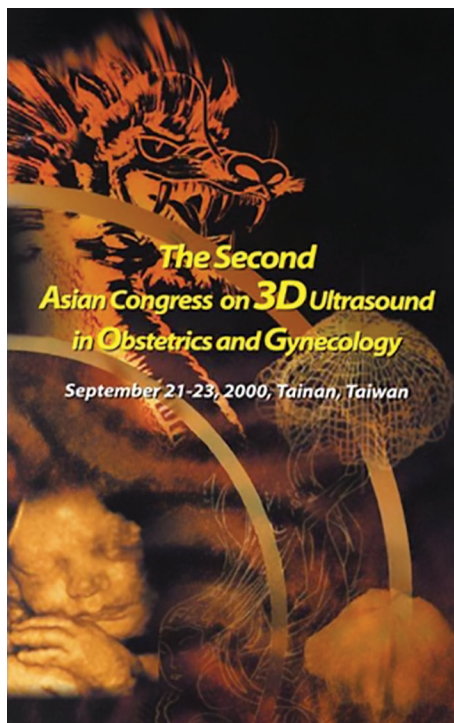


Fig. 1: Left: Announcement of the First World Congress on 3D Ultrasound in Obstetrics and Gynecology in Mainz, Germany. Right: Announcement of the Second World Congress on 3D Ultrasound in Obstetrics and Gynecology in Las Vegas, USA

anomalies of the brain, the face, thorax, heart and the vascular system, abdominal wall defects, spina bifida, and urogenital and limb malformations.⁷⁻²⁶ One of the latest developments in 3D ultrasound is the HDlive mode that enables a near photographic demonstration of the surface of the embryo and fetus.^{19,25,27} HDlive uses a movable virtual light source for illumination of the object of interest. The combination of light and shadow increases depth perception and produces more natural pictures than those obtained with classic 3D surface modes. HDlive

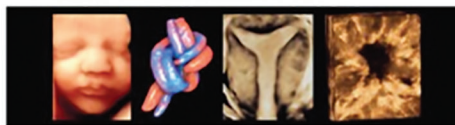
Studio allows illumination of the embryo/fetus with 3 different movable light sources, similar to the illumination of an actor on a stage. Another new technology is the Silhouette mode, in particular, the high Silhouette mode that allows demonstration of inner organs, such as the ventricle system of the brain²⁸ or the bowel in the umbilical cord during umbilical herniation.²⁹ With the different display modes, even subtle defects which are important in syndromes or chromosomal aberrations can be demonstrated. The 4D ultrasound enables the control of fetal movements in real time while observing the fetal surface. Normal and abnormal movements permit insights into fetal neurodevelopment.³⁰⁻³² Normal, borderline, and abnormal behavior in fetuses from low-risk and high-risk pregnancies can be differentiated by use of the Kurjak Antenatal Neurodevelopment Test.^{33,34} Spatiotemporal image correlation (STIC) permits offline multiplanar analysis of the fetal heart in motion.^{35,36} The combination of STIC and color Doppler provides the examiner with a detailed view of the cardiac blood flow. This allows the examiner to view complex anomalies of the fetal heart and to control the cardiac blood flow during the different heart cycles.^{4,37-40}

In gynecology, 3D ultrasound^{41,42} can be applied in the diagnosis of pelvic floor defects,^{43,44} uterus anomalies,^{42,45,46} or fertility problems as well as in the identification of tubal patency (HYCOSY)⁴⁷⁻⁵³ or uterine device location^{42,54,55} as well as in tumor evaluation and differentiation.^{42,56-59} In particular, the combination of 3D



11. SYMPOSIUM

3D/4D - SONOGRAPHIE in Gynäkologie und Geburtshilfe



REFERENTEN:

- Alexich, S. B., Frauenklinik Kiel, Mönchen
- Benois, B., Nizza, Frankreich
- Bonilla-Masdes, F., Uten, Valencia, Spanien
- Burdil, H., Zgib, Österreich
- Chavira, R., Praxis für Privatmedizin, Berlin
- Dachauer, H., Seligen
- Farnik, A., Unik-Frauenklinik, Kiel
- Genesick, H., Karlsruher Institut für Technologie
- Hilgig, K. S., Praxis für Privatmedizin, Berlin
- Hornick, W., Unik-Frauenklinik, Berlin
- Kurjak, A., Universitäts-Zagreb, Kroatien
- Merz, E., Zentrum für Ultraschall u. Privatmedizin, Frankfurt/Main
- Miya-Tanaka, D., Poliklinika Gynaecol., Zagreb, Kroatien
- Paßat, S., Zentrum für Ultraschall u. Privatmedizin, Frankfurt/Main
- Rain, L., Institut für, Bern, Schweiz
- Schild, R., Privatambulanz, Hannover

E-Mail: ultraschallzentrum_frankfurt@web.de
ultraschallzentrum_veranstaltung@gmx.de

09. - 10.03.2018

Frankfurt am Main
 Kommunikationszentrum
 am Krankenhaus Nordwest



DEGUM (Deutsche Gesellschaft für Ultraschall in der Gynäkologie und Geburtshilfe)

Veranstalter und Leitung:
 Prof. Dr. med. Prof. h.c. E. Merz
 Vorsitzender der FMF-Deutschland
 Director, German Branch of Ian Donald School
 Zentrum für Ultraschall u. Privatmedizin
 Frankfurt am Main

Telefon 069 - 7601 - 3716

Fig. 2: Left: Announcement of the Second Asian Congress on 3D Ultrasound in Obstetrics and Gynecology in Tainan, Taiwan. Right: Announcement of the 11th Symposium on 3D Ultrasound in Obstetrics and Gynecology in Frankfurt, Germany

ultrasound and Color Doppler permits the demonstration of the spatial pattern of tumor vascularization.^{42,60,61}

In breast diagnosis, 3D ultrasound⁶²⁻⁶⁶ provides additional information in the multiplanar mode. The third plane parallel to the thorax enables the detection of the retraction pattern typical for malignant tumors.^{62,63} The 3D ultrasound offers another important advantage during the puncture of breast tumors: Control of the needle in all three planes enables a precise puncture of the tumor.^{67,68}

The digital storage of volumes permits a virtual examination, i.e., volumes can be reloaded at any time and examined in the absence of the patient.^{4,25} With the help of a special computer program, all stored volumes can be loaded on a computer and thus be examined independently of the ultrasound unit.³⁻⁶ Digital storing of volumes further enables a perfect teaching approach in medical education. Reviewing copies of a stored volume allows several trainees to be taught at the same time enabling them to recognize the fetal anatomy hidden within the volume.³

In conclusion, 3D/4D ultrasound has profited greatly from the developments in computer and 3D probe technology. It has become such a sophisticated technique in the fields of prenatal diagnosis, gynecology, and breast diagnosis that it is indispensable for the skilled ultrasound operator. It represents a problem-solving tool in different circumstances, not only in the demonstration of pathological findings, but also in the verification of normal findings. This is particularly important in obstetrics in patients with an increased risk for a specific fetal malformation. In such a situation, the parents-to-be can easily be reassured by being shown the normal fetal anatomy. On the contrary, with the ability to demonstrate the fetus to the parents-to-be as in a photograph, there may be a risk that they believe 3D ultrasound to be able to detect any possible defect and can thus guarantee the "perfect baby."⁶⁹ However, this would definitively be the wrong conclusion.

REFERENCES

1. Szilard J. An improved three-dimensional display system. *Ultrasonics* 1974 Nov;12(6):273-276.
2. Kirbach D, Whittingham TA. 3D ultrasound—the Kretztechnik Voluson® approach. *Eur J Ultrasound* 1994;1:85-89.
3. Merz E. 25 years of 3D ultrasound in prenatal diagnosis (1989-2014). *Ultraschall Med* 2015 Feb;36(1):2-8.
4. Merz E. 3-D ultrasound in prenatal diagnosis. In: Merz E, ed. *Ultrasound in obstetrics and gynecology*. Vol. 1: Obstetrics. New York: Thieme Stuttgart; 2005. pp. 516-528.
5. Merz E. Current 3D/4D ultrasound technology in prenatal diagnosis. *Eur Clin Obstet Gynaecol* 2005;1:184-193.
6. Merz E, Abramowicz JS. 3D/4D ultrasound in prenatal diagnosis: is it time for routine use? *Clin Obstet Gynecol* 2012 Mar;55(1):336-351.
7. Merz E, Weber G, Bahlmann F, Miric-Tesanic D. Application of transvaginal and abdominal three-dimensional ultrasound for the detection or exclusion of malformations of the fetal face. *Ultrasound Obstet Gynecol* 1997 Apr;9(4):237-243.
8. Baba K, Okai T, Kozuma S, Taketani Y. Fetal abnormalities: evaluation with real-time-processible three-dimensional US—preliminary report. *Radiology* 1999 May;211(2):441-446.
9. Timor-Tritsch IE, Monteagudo A, Mayberry P. Three-dimensional ultrasound evaluation of the fetal brain: the three horn view. *Ultrasound Obstet Gynecol* 2000 Sep;16(4):302-306.
10. Rotten D, Levailant JM. Two-and three-dimensional sonographic assessment of the fetal face. 2. Analysis of cleft lip, alveolus and palate. *Ultrasound Obstet Gynecol* 2004 Sep;24(4):402-411.
11. Benacerraf BR, Benson CB, Abuhamad AZ, Copel JA, Abramowicz JS, Devore GR, Doubilet PM, Lee W, Lev-Toaff AS, Merz E, et al. Three- and 4-dimensional ultrasound in obstetrics and gynecology: proceedings of the American Institute of Ultrasound in Medicine Consensus Conference. *J Ultrasound Med* 2005 Dec;24(12):1587-1597.
12. Merz E, Welter C. 2D and 3D ultrasound evaluation of normal and abnormal fetal anatomy in the second and third trimesters in a level III center. *Ultraschall Med* 2005 Feb;26(1):9-16.
13. Benoit B, Chaoui R. Three-dimensional ultrasound with maximal mode rendering: a novel technique for the diagnosis of bilateral or unilateral absence or hypoplasia of nasal bones in second-trimester screening for Down syndrome. *Ultrasound Obstet Gynecol* 2005 Jan;25(1):19-24.
14. Merz E, Benoit B, Blass HG, Baba K, Kratochwil A, Nelson T, Pretorius D, Jurkovic D, Chang FM, Lee A. Standardization of three-dimensional images in obstetrics and gynecology: consensus statement. *Ultrasound Obstet Gynecol* 2007 Jun;29(6):697-703.
15. Merz E, Abramowicz J, Baba K, Blaas HG, Deng J, Gindes L, Lee W, Platt L, Pretorius D, Schild R, et al. 3D imaging of the fetal face—recommendations from the International 3D Focus Group. *Ultraschall Med* 2012 Apr;33(2):175-182.
16. Andresen C, Matias A, Merz E. Fetal face: the whole picture. *Ultraschall Med* 2012 Oct;33(5):431-440.
17. El Guindi W, Dreyfus M, Carles G, Lambert V, Herlicoviez M, Benoit G. 3D ultrasound and Doppler angiography for evaluation of fetal cardiovascular anomalies. *Int J Gynaecol Obstet* 2013 Feb;120(2):173-177.
18. Pashaj S, Merz E, Wellek S. Biometric measurements of the fetal corpus callosum by three-dimensional ultrasound. *Ultrasound Obstet Gynecol* 2013 Dec;42(6):691-698.
19. Bonilla-Musoles F, Raga F, Osborne NG, Bonilla F Jr, Caballero O, Climent MT, Wallraf SH, Castillo JC. Multimodality 3-dimensional volumetric ultrasound in obstetrics and gynecology with an emphasis in HDlive technique. *Ultrasound Q* 2013 Sep;29(3):189-201.
20. Pashaj S, Merz E. Prenatal demonstration of normal variants of the pericallosal artery by 3D ultrasound. *Ultraschall Med* 2014 Apr;35(2):129-136.
21. Tonni G, Grisolia G, Sepulveda W. Second trimester fetal neurosonography: reconstructing cerebral midline anatomy and anomalies using a novel three-dimensional ultrasound technique. *Prenat Diagn* 2014 Jan;34(1):75-83.
22. Leibovitz Z, Haratz KK, Malinger G, Shapiro I, Pressman C. Fetal posterior fossa dimensions: normal and anomalous development assessed in mid-sagittal cranial plane by

- three-dimensional multiplanar sonography. *Ultrasound Obstet Gynecol* 2014 Feb;43(2):147-153.
23. Pashaj S, Merz E. Detection of fetal corpus callosum abnormalities by means of 3D ultrasound. *Ultraschall Med* 2016 Apr;37(2):185-194.
 24. Tutschek B, Blaas HK, Abramowicz J, Baba K, Deng J, Lee W, Merz E, Platt L, Pretorius D, Timor-Tritsch IE, et al. Three-dimensional ultrasound imaging of the fetal skull and face. *Ultrasound Obstet Gynecol* 2017 Jul;50(1):7-16.
 25. Merz E, Pashaj S. Advantages of 3D ultrasound in the assessment of fetal abnormalities. *J Perinat Med* 2017 Aug 28;45(6):643-650.
 26. Merz E, Pashaj S. True or false umbilical cord knot? Differentiation via 3D/4D color Doppler ultrasound. *Ultraschall Med* 2018 Apr;39(2):127-128.
 27. Pooh RK, Kurjak A. Novel application of three-dimensional HDlive imaging in prenatal diagnosis from the first trimester. *J Perinat Med* 2015 Mar;43(2):147-158.
 28. Pooh RK. "See-through fashion" in prenatal diagnostic imaging. *Donald School J Ultrasound Obstet Gynecol* 2015;9:111.
 29. Merz E. Physiological umbilical herniation—a distinctive sonographic feature in the embryonic stage. *Ultraschall Med* 2017 Apr;38(2):123-124.
 30. Kurjak A, Barisic LS, Stanojevic M, Porovic S. Are we ready to investigate cognitive function of fetal brain? The role of advanced four-dimensional sonography. *Donald School J Ultrasound Obstet Gynecol* 2016 Jan;10(2):116-124.
 31. Salihagić-Kadić A, Kurjak A. Cognitive function of the fetus. *Ultraschall Med* 2018 Apr;39(2):181-189.
 32. Stanojevic M, Kurjak A, Salihagić-Kadić A, Vasilj O, Miskovic B, Shaddad AN, Ahmed B, Tomasović S. Neurobehavioral continuity from fetus to neonate. *J Perinat Med* 2011 Mar;39(2):171-177.
 33. Kurjak A, Miskovic B, Stanojevic M, Amiel-Tison C, Ahmed B, Azumendi G, Andonotopo W, Turudic T, Salihagić-Kadić A. New scoring system for fetal neurobehaviour assessed by three- and four-dimensional sonography. *J Perinat Med* 2008;36(1):73-81.
 34. Kurjak A, Antsaklis P, Stanojevic M, Vladareanu R, Vladareanu S, Neto RM, Barisic LS, Porovic S, Delic T. Multicentric studies of the fetal neurobehavior by KANET test. *J Perinat Med* 2017 Aug;45(6):717-727.
 35. Devore GR, Falkensammer P, Sklansky MS, Platt LD. Spatiotemporal image correlation (STIC): new technology for evaluation of the fetal heart. *Ultrasound Obstet Gynecol* 2003 Oct;22(4):380-387.
 36. Chaoui R, Heling KS. New developments in fetal heart scanning: three- and four-dimensional fetal echocardiography. *Semin Fetal Neonatal Med* 2005 Dec;10(6):567-577.
 37. Hata T, AboEllail MA, Sajapala S, Ishimura M, Masaoka H. HDlive Silhouette mode with spatiotemporal image correlation for assessment of the fetal heart. *J Ultrasound Med* 2016 Jul;35(7):1489-1495.
 38. DeVore GR, Satou G, Sklansky M. 4D fetal echocardiography—an update. *Echocardiography* 2017 Dec;34(12):1788-1798.
 39. Tedesco GD, de Souza Bezerra M, Barros FS, Martins WP, Nardoza LM, Carrilho MC, Moron AF, Carvalho FH, Rolo LC, Araujo Júnior E. Reference ranges of fetal cardiac biometric parameters using three-dimensional ultrasound with spatiotemporal image correlation M mode and their applicability in congenital heart diseases. *Pediatr Cardiol* 2017 Feb;38(2):271-279.
 40. Guasina F, Bellussi F, Morganelli G, Salsi G, Pilu G, Simonazzi G. Electronic spatiotemporal image correlation improves four-dimensional fetal echocardiography. *Ultrasound Obstet Gynecol* 2018 Mar;51(3):357-360.
 41. Merz E, Pashaj S. Current role of 3D/4D sonography in obstetrics and gynecology. *Donald School J Ultrasound Obstet Gynecol* 2013;7(4):400-408.
 42. Merz E. Transvaginal 3D/4D ultrasound and its application in gynecology. In: Merz E, ed. *Ultrasound in obstetrics and gynecology*. Vol. 2: Gynecology. New York, Stuttgart: Thieme; 2007. pp. 222-240.
 43. Dietz HP. Ultrasound imaging of the pelvic floor. Part II: three-dimensional or volume imaging. *Ultrasound Obstet Gynecol* 2004 Jun;23(6):615-625.
 44. Dietz HP, Moegni F, Shek KL. Diagnosis of levator avulsion injury: a comparison of three methods. *Ultrasound Obstet Gynecol* 2012;40:693-698.
 45. Moini A, Mohammadi S, Hosseini R, Eslami B, Ahmadi F. Accuracy of 3-dimensional sonography for diagnosis and classification of congenital uterine anomalies. *J Ultrasound Med* 2013 Jun;32(6):923-927.
 46. Tabi S, Kupesic Plavsic S. The role of three-dimensional ultrasound in the assessment of congenital uterine anomalies. *Donald School J Ultrasound Obstet Gynecol* 2012;6(4):415-423.
 47. Jurkovic D, Geipel A, Gruboeck K, Jauniaux E, Natucci M, Campbell S. Three-dimensional ultrasound for the assessment of uterine anatomy and detection of congenital anomalies: a comparison with hysterosalpingography and two-dimensional sonography. *Ultrasound Obstet Gynecol* 1995 Apr;5(4):233-237.
 48. Mercé LT, Barco MJ, Bau S, Troyano JM. Prediction of ovarian response and IVF/ICSI outcome by three-dimensional ultrasound and power Doppler angiography. *Eur J Obstet Gynecol Reprod Biol* 2007 May;132(1):93-100.
 49. Zhang T, He Y, Wang Y, Zhu Q, Yang J, Zhao X, Sun Y. The role of three-dimensional power Doppler ultrasound parameters measured on hCG day in the prediction of pregnancy during in vitro fertilization treatment. *Eur J Obstet Gynecol Reprod Biol* 2016 Aug;203:66-71.
 50. Maged AM, Ramzy AM, Ghar MA, El Shenoufy H, Gad Allah SH, Wahba AH, ElKateb AY, Hwedi N. 3D ultrasound assessment of endometrial junctional zone anatomy as a predictor of the outcome of ICSI cycles. *Eur J Obstet Gynecol Reprod Biol* 2017 May;212:160-165.
 51. Raine-Fenning N, Jayaprakasan K, Clewes J, Joergner I, Bonaki SD, Chamberlain S, Devlin L, Priddle H, Johnson I. SonoAVC: a novel method of automatic volume calculation. *Ultrasound Obstet Gynecol* 2008 Jun;31(6):691-696.
 52. Zhou L, Zhang X, Chen X, Liao L, Pan R, Zhou N, Di N. Value of three-dimensional hysterosalpingo-contrast sonography with SonoVue in the assessment of tubal patency. *Ultrasound Obstet Gynecol* 2012 Jul;40(1):93-98.
 53. Exacoustos C, Di Giovanni A, Szabolcs B, Romeo V, Romanini ME, Luciano D, Zupi E, Arduini D. Automated three-dimensional coded contrast imaging hysterosalpingo-contrast sonography: feasibility in office tubal patency testing. *Ultrasound Obstet Gynecol* 2013 Mar;41(3):328-335.
 54. Bonilla-Musoles F, Raga F, Osborne NG, Blanes J. Control of intrauterine device insertion with three-dimensional ultrasound: is it the future? *J Clin Ultrasound* 1996 Jun;24(5):263-267.

55. Benacerraf BR, Shipp TD, Bromley B. Three-dimensional ultrasound detection of abnormally located intrauterine contraceptive devices which are a source of pelvic pain and abnormal bleeding. *Ultrasound Obstet Gynecol* 2009 Jul;34(1): 110-115.
56. Chou CY, Hsu KF, Wang ST, Huang SC, Tzeng CC, Huang KE. Accuracy of three-dimensional ultrasonography in volume estimation of cervical carcinoma. *Gynecol Oncol* 1997 Jul;66(1): 89-93.
57. Alcazar JL, Jurado M. Three-dimensional ultrasound for assessing women with gynecological cancer: a systematic review. *Gynecol Oncol* 2011 Mar;120(3):340-346.
58. Pascual MA, Graupera B, Hereter L, Rotili A, Rodriguez I, Alcazar JL. Intra- and interobserver variability of 2D and 3D transvaginal sonography in the diagnosis of benign versus malignant adnexal masses. *J Clin Ultrasound* 2011 Jul;39(6):316-321.
59. Acharya UR, Sree SV, Krishnan MM, Saba L, Molinari F, Guerriero S, Suri JS. Ovarian tumor characterization using 3D ultrasound. *Technol Cancer Res Treat* 2012 Dec;11(6):543-552.
60. Belitsos P, Papoutsis D, Rodolakis A, Mesogitis S, Antsaklis A. Three-dimensional power Doppler ultrasound for the study of cervical cancer and precancerous lesions. *Ultrasound Obstet Gynecol* 2012 Nov;40(5):576-581.
61. Perez-Medina T, Orensanz I, Pereira A, Valero de Bernabé J, Engels V, Troyano J, SanFrutos L, Iglesias E. Three-dimensional angioultrasonography for the prediction of malignancy in ovarian masses. *Gynecol Obstet Invest* 2013;75(2):120-125.
62. Rotten D, Levailant JM, Zerat L. Analysis of normal breast tissue and of solid breast masse using three-dimensional ultrasound mammography. *Ultrasound Obstet Gynecol* 1999 Aug;14(2):114-124.
63. Merz E, Oberstein A. 3D and 4D breast ultrasound. In: *Ultrasound in obstetrics and gynecology*. Vol. 2: Gynecology. New York: Thieme Stuttgart; 2007. pp. 266-296.
64. Weismann C, Mayr C, Egger H, Auer A. Breast sonography—2D, 3D, 4D ultrasound or elastography? *Breast Care* 2011;6:98-103.
65. Vourtsis A, Kachulis A. The performance of 3D ABUS versus HHUS in the visualisation and BI-RADS characterisation of breast lesions in a large cohort of 1,886 women. *Eur Radiol* 2018 Feb;28(2):592-601.
66. Meel-van den Abeelen AS, Weijers G, van Zelst JC, Thijssen JM, Mann RM, de Korte CL. 3D quantitative breast ultrasound analysis for differentiating fibroadenomas and carcinomas smaller than 1 cm. *Eur J Radiol* 2017 Mar;88:141-147.
67. Weismann CF, Forstner R, Prokop E, Rettenbacher T. Three-dimensional targeting: a new three-dimensional ultrasound technique to evaluate needle position during breast biopsy. *Ultrasound Obstet Gynecol* 2000 Sep;16(4):359-364.
68. Delle Chiaie L, Terinde R. Three-dimensional ultrasound-validated large-core needle biopsy: is it a reliable method for the histological assessment of breast lesions? *Ultrasound Obstet Gynecol* 2004 Apr;23(4):393-397.
69. Kurjak A. 3D/4D sonography (Editorial). *J Perinat Med* 2017 Aug 28;45(6):639-641.