

## CASE REPORT

# HDlive and Three-Dimensional Imaging in Prenatal Diagnosis of Sirenomelia in the First Trimester: A Case Report and Brief Review of the Literature

<sup>1</sup>Fernando Bonilla-Musoles, <sup>2</sup>Oscar Caballero, <sup>3</sup>Juan Carlos Castillo, <sup>4</sup>Francisco Bonilla Jr, <sup>5</sup>Francisco Raga

## ABSTRACT

Herein a case of sirenomelia diagnosed in week 12 by using HDlive and three-dimensional (3D) imaging. These new technologies allowed for an early diagnosis and also depicting realistic images.

**Keywords:** HDlive, Prenatal diagnosis, Sirenomelia, Three-dimensional ultrasound.

**How to cite this article:** Bonilla-Musoles F, Caballero O, Castillo JC, Bonilla F Jr, Raga F. HDlive and Three-Dimensional Imaging in Prenatal Diagnosis of Sirenomelia in the First Trimester: A Case Report and Brief Review of the Literature. Donald School J Ultrasound Obstet Gynecol 2015;9(2):193-196.

**Source of support:** Nil

**Conflict of interest:** None

## INTRODUCTION

Sirenomelia is an extremely rare congenital malformation characterized by fusion and atrophies of the lower limbs depicting the aspect of a 'mermaid's tail' the mitologic image of a woman with a fish-like inferior half of the body. Sirenomelia is usually considered the most severe form of caudal regression syndrome,<sup>1</sup> while others consider it an independent entity.<sup>2,3</sup>

Herein we describe a non-invasive prenatal diagnosis of sirenomelia using state-of-the-art three-dimensional (3D) ultrasonographic modalities in the first trimester of pregnancy.

## CASE REPORT

A 22-year-old patient, gravida 1, para 0, was referred to our Hospital, at 12 weeks of pregnancy with a suspected diagnosis of sirenomelia based on a two-dimensional

(2D) transvaginal US exam. The pregnancy was naturally conceived and the medical background was judged as noncontributory when relevant factors such as consanguinity, drug exposure, alcohol abuse, diabetes or hypertension were excluded.

The ultrasonographic evaluation was performed Voluson E8 scanner (GE Healthcare, Kretz, Zipf, Austria) equipped with a convex 4 to 8 MHz abdominal transducer and a 6 to 12 MHz endovaginal probe both adapted with color and power Doppler as well as 3D/4D and HDlive software.

The initial sonographic transvaginal exam using tomographic ultrasound imaging (TUI) view showed a fetus with normal cardiac activity, normal amniotic fluid, and upper limbs of normal appearance and moving normally. The single fetus had a crown-rump length of 58.6, the nasal bone was clearly seen and the nuchal translucency measured 1, 2 mm. All the neurological structures were normal (Fig. 1). Conventional 3D US and HDlive were applied in order to obtain a detailed evaluation, showing that the lower limbs appeared lean and fused together in fixed extension, with only one femur, remnants of one tibia and absence of feet (Fig. 2). The pelvis region was ambiguous and the bladder, kidneys or extern genitalia were not visible. Consent for abortion was given and postmortem analysis confirmed the presence of only one femur and a hypotrophic tibia, also a intact uterus, a single umbilical artery and anal imperforation were found. The cariotype was 46,XX.

## DISCUSSION

The word sirenomelia is derived from the greek words 'seiren' meaning siren or 'mermaid' and 'melos' meaning 'limb'. This congenital malformation is estimated to occur in 1 out of 60,000 pregnancies.<sup>13</sup>

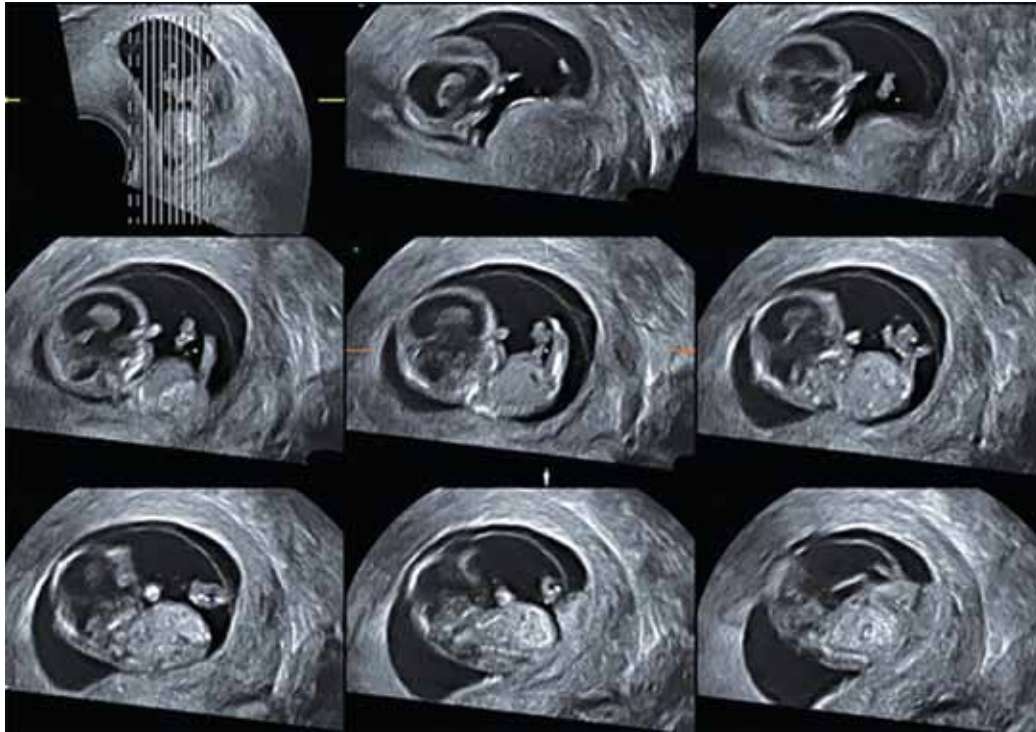
Sirenomelia or the mermaid syndrome is a rare congenital malformation. The condition is frequently lethal, but the medical literature describes some exceptional cases with variable survival rate after birth.<sup>19,20,34</sup>

The ancient mythology represents mermaids as female (Copenhagen's mermaid is a typical example), but the truth is that male sex is predominant among the condition with a 3:1 rate.<sup>18-21</sup>

<sup>1</sup>Professor, <sup>2</sup>PhD (Biochemistry), <sup>3</sup>PhD, <sup>4,5</sup>Assistant Professor  
<sup>1,2,4,5</sup>Department of Obstetrics and Gynecology, School of Medicine  
University of Valencia, Navarro Reverter, Valencia, Spain

<sup>3</sup>Instituto Bernabe, Alicante, Spain

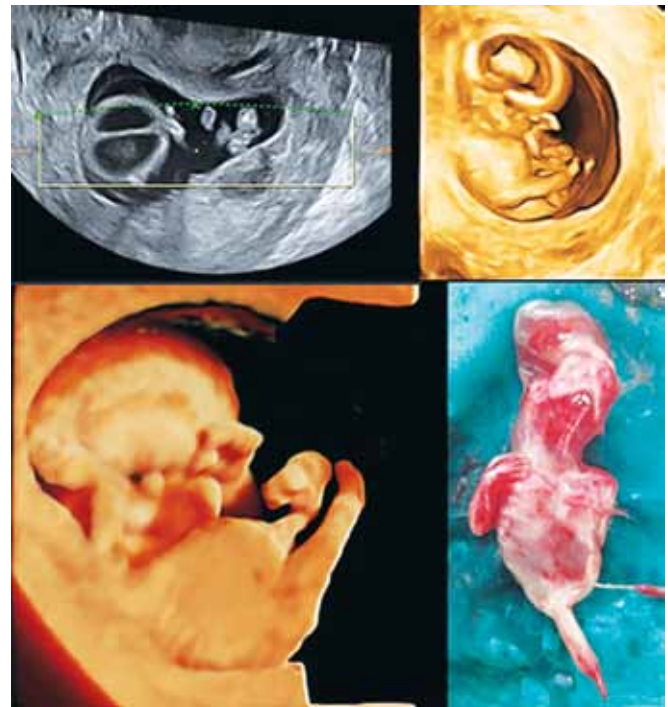**Corresponding Author:** Fernando Bonilla-Musoles, Professor  
Department of Obstetrics and Gynecology, School of Medicine  
University of Valencia, Navarro Reverter 11, 46004 Valencia  
Spain, Phone: 0034963515477, e-mail: profesor.bonillamusoles@hotmail.com



**Fig. 1:** Tomographic ultrasound imaging (TUI) of the fetus showing a normal upper half of the body with both upper limbs seen separately and moving normally. The lower limbs appeared fused

The etiology of the condition remains elusive, but it has been associated to a variety of conditions, such as diabetes,<sup>22</sup> cocaine consumption in the first week of pregnancy,<sup>23</sup> overexposure to high doses of etretinato,<sup>24,25</sup> cyclophosphamide<sup>27</sup> trimethoprim,<sup>9</sup> or to assisted reproduction techniques (mainly ICSI).<sup>26</sup> The latter two associations were confirmed in animal experimentation.

Although several hypotheses have been postulated as the origin of the malformation, the exact etiology of the syndrome remains unknown. A damage occurring early during embryonic development in the caudal mesoderm was initially proposed by some authors<sup>28</sup> as to the cause of the limb malformation. This event may result in merging, malrotation and dysgenesis of the lower extremities. Gardner and Breuer (1980)<sup>29</sup> postulated that the overdistention of the caudal portion of the neural tube may cause a lateral rotation of mesoderm and the fusion of the early inferior limbs. Later experiments in rodents exposed to high doses of retinoic acid confirmed that an early interference in the process of gastrulation was correlated to the caudal dysgenesis syndrome and congenital lower limb malformations.<sup>30</sup> The 'vascular steal' phenomenon due to aberrant vasculature, which impairs blood flow to the lower part of the body, resulting in abnormal development was also hypothesized as to the origin of the syndrome. A common feature in the mermaid syndrome is the presence of a single large umbilical artery. Arteries below the level of this steal vessel are underdeveloped and tissues dependent upon



**Fig. 2:** Above 2D (left) and 3D US (right) showing clearly the siren or mermaid cauda which is especially clear using HDLive

them for nutrient supply fail to develop properly. This hypothesis suggest that the single lower extremity in sirenomelia results from a failure of the lower limb bud field to be cleaved into two lateral masses rather than of a limb fusion phenomenon.<sup>31</sup>

The use of prenatal ultrasound in the diagnosis of this rare congenital lower extremity deformity syndrome

was first described in the early eighties.<sup>3</sup> Following those first reports, the advancement of US scan technology allowed for earlier diagnosis at early third/second<sup>4,6</sup> and first trimesters by using transvaginal probes,<sup>5,7-18</sup> moreover the image quality was highly increased with the use of advanced US technologies, such as Doppler and 3D scan.<sup>4,5,12,15,33</sup> The first diagnostic clue is usually the presence of oligoamnios (mainly during second trimester scans), due to the bilateral kidney agenesis associated to this pathology. Ultrasonographic confirmation is not always easy, since the morphologic study of the fetus is impaired by the diminished amount of amniotic fluid.<sup>4,5,32</sup>

Summarizing a new case of sirenomelia diagnosed in the first trimester by using 2D/3D/4D and HDLive is showed. These new US technologies brought much more clearly pictures.

## REFERENCES

- Nyberg DA, Mahoney BS, Pretorius DH. Diagnostic ultrasound of fetal anomalies: text and atlas. Chicago. Year Book Medical Publish 1989:189-190.
- Twickler D, Budorick N, Pretorius DH, Grafe M, Currarino G. Caudal Regression versus sirenomelia: sonographic clues J Clin Ultrasound 1993;12(3):313-330.
- Fiegler W, Hunsdiek FW. The value of radiological and ultrasound examination in the prenatal diagnosis of the siren syndrome (author's transl). Rofo 1980 Nov;133(5):539-542.
- Monzó A, Sanchez-Serrano M, Navarro-Fos S, Torres JV, Bonilla-Musoles F. La sirenomelia: Diagnóstico prenatal e hipótesis etiológica. A propósito de un caso. Obstet Ginecol Españ 1999;8(4):213-216.
- Singh Ch, Lodha P, Arora D, Sharma AP, Kaul A. Diagnosis of sirenomelia in the first trimester: case report. J Clin Ultrasound 2014;42(6):355-359.
- Chenoweth CK, Kellog SJ, Abu-Yousef MM. Antenatal sonographic diagnosis of sirenomelia. J Clin Ultrasound 1991;19(2):167-170.
- Van Zählen-Sprock MM, Van Vugt JMG, Van der Harter JJ, Van Geijn HP. Early second trimester diagnosis of sirenomelia. Prenatal Diagn 1995;15(2):171-177.
- Schiesser M, Holzgreve W, Lapaire O, Willi N, Lüthi H, Lopez R, Tercanli S. Sirenomelia the mermaid syndrome-detection in the first trimester. Prenat Diagn 2003;23(3):493-496.
- Dosedla E, Kalafusová M, Calda P. Sirenomelia apus after trimethoprim exposure: first trimester ultrasound diagnosis. J Clin Ultrasound 2012;40(9):594-597.
- Van Keirsbilck J, Cannie M, Robrechts C, De Ravel T, Dymarkowski S, Van den Bosch T, Van Schoubroeck D. First trimester diagnosis of sirenomelia. Prenat Diagn 2006;26(5):684-688.
- Carbillon L, Seince N, Largillière C, Bucourt M, Uzan M. First-trimester diagnosis of sirenomelia. A case report. Fetal Diagn Ther 2001;16(3):284-288.
- Monteagudo A, Mayberry P, Rebarber A, Paidas M, Timor-Tritsch IE. Sirenomelia sequence: first-trimester diagnosis with both two- and three-dimensional sonography. J Ultrasound Med 2002;21(1):915-920.
- Sirtori M, Ghidini A, Romero R, Hobbins JC. Prenatal Diagnosis of sirenomelia. J Ultrasound Med 1989;8(7):83-87.
- Harika G, Gabriel R, Bory JP, Gaillard D, Quereux C, Walh P. Sirenomelus. Case report and review of nosology. J Gynecol Obstet Biol Reprod 1995;24(1):49-51.
- Contu R, Zoppi MA, Axiana C, Ibba RM, Monni G. First trimester diagnosis of sirenomelia by 2D and 3D ultrasound. Fetal Diagn Ther 2009;26(1):41-44.
- Akbayir O, Gungorduk K, Sudolmus S, Gulkilik A, Ark C. First trimester diagnosis of sirenomelia: a case report and review of the literature. Arch Gynecol Obstet 2008;278(5):589-592.
- Clemente CM, Farina M, Cianci A, Iraci Sareri M. Sirenomelia with oligodactylia: early ultrasonographic and hysteroscopic embryoscopic diagnosis during the first trimester of gestation. Fetal Diagn Ther 2010;28:43-45.
- Cuillier F, Mardamootoo D, Lamarque M, Cerisier S, Bideaut J. Three-dimensional sonography of sirenomelia at 10 and 12 weeks' gestation. J Ultrasound Med 2013;32(10):1678-1680.
- Murphy JJ, Fraser GC, Blair GK. Sirenomelia: case of surviving mermaid. J Pediatr Surg 1992;27:1265-1268.
- Clarke LA, Stinger DA, Fraser GC, Yong SL. Long term survival of an infant with sirenomelia. Am J Med Genet 1993;45:292-296.
- Jones KL. Smith's recognizable patterns of human malformations. Genetic, Embriologic and Clinical Aspects. 4th Ed. Philadelphia. Saunders WB 1988:574-592.
- Mills JL. Malformations in infants of diabetic mothers. Teratology 1982;9:99-112.
- Sarpong S, Haedings V. Sirenomelia accompanying exposure to the embryo to cocaine. South Med J 1992;85:545-547.
- Kapur RP, Mahony BS, Nyberg DA, Resta RG, Shepard TH. Sirenomelia associated a 'vanishing twin'. Teratology 1991;43:103-109.
- Mesrobian HGJ, Sessions RP, Lloyd RA, Sulik KK. Cloacal and urogenital abnormalities induced by etretinate in mice. J Urol 1994;152:675-678.
- Bakhtar O, Benirschke K, Masliah E. Sirenomelia of an intracytoplasmic sperm injection conceptus: a case report and review of mechanism. Pediatr Dev Pathol. 2006;9:245-253.
- Manson JM, Smith CC. Influence of cyclophosphamide and 4-ketocyclophosphamide on mouse limb development. Teratology 1977;15:291-299.
- Kallen B, Winberg J. Caudal mesoderm pattern of anomalies: from renal agenesis to sirenomelia. Teratology. 1973;25:385-394.
- Gardner NJ, Breuer AC. Anomalies of heart, spleen, kidneys, gut and limbs, may result from a overdistended neural tube. A hypothesis. Pediatrics 1980;65:508-519.
- Alles AS, Sulik KK. A review of caudal dysgenesis and its pathogenesis as illustrated in an animal model. Birth defects 1993;23:83-102.
- Stevenson RE, Lyon Jones K, Phelan MC, Jones MC, Barr M, Clericuzio C, Harley RA, Benirschke K. Vascular steal: the pathogenetic mechanism producing sirenomelia and

- associated defects of the viscera and soft tissues. *Pediatrics* 1986;78:451-457.
32. Sepulveda W, Corral E, Sanchez J, Carstens E, Schnapp C. Sirenomelia sequence versus renal agenesis: prenatal differentiation with power Doppler ultrasound. *Ultrasound ObstetGynecol* 1998;11(10):4459.
33. Tonni G, Grisolia G. Sirenomelia: a review on embriogenic theories, novel three-dimensional ultrasound imaging and first trimester diagnosis in a case of mosaic 69,XXX/46,XX fetus. *Arch Gynecol Obstet.* 2013;288(2):3-11.
34. Palacios Carbajal OF, Villate Alvarado HP, Aquino Díaz G, Salazar Moreno C. Sirenomelia, Reporte de un caso. *Diagnóstico (Perú)* 2008;47(1):88-90.
35. Andrés Estay F, Hugo Benítez C, Roxana Parra L. Un caso de sirenomelia con cariotipo isocromosoma 18q en mosaico. *Rev Chil Obstet Ginecol* 2008;73(4):268-272.