

# Antenatal Cerebral Hemorrhages: Evolution and Outcome

<sup>1</sup>Dimitrie Pelinescu-Onciul, <sup>2</sup>Adrian Ioan Toma, <sup>3</sup>Mihaela Steriu, <sup>4</sup>Aura Irina Cuzino, <sup>5</sup>Caliochia Gavril-Parfene, <sup>6</sup>Alexandra Cozinov, <sup>7</sup>Raluca Olteanu, <sup>8</sup>Dana Craiu

## ABSTRACT

Cerebral hemorrhage can affect the fetus. Clinical signs usually suggest the presence of cerebral hemorrhage and it can be confirmed by ultrasound during the fetal or early neonatal period. The first part of this paper investigates the usefulness of neonatal cerebral ultrasound screening in term neonates, in order to detect antenatal/perinatal cerebral hemorrhage. Three newborns with antenatal cerebral hemorrhage are presented. A diagnosis and investigation algorithm consisting of five questions is proposed for each case: 'When did the hemorrhage occur?', 'What is the diagnosis?', 'Are there neonatal consequences?' 'Other lesions?' and 'What is the prognosis?'.

**Keywords:** Cerebral hemorrhage, Antenatal, Ultrasound, Diagnostic algorithm.

**How to cite this article:** Pelinescu-Onciul D, Toma AI, Steriu M, Cuzino AI, Gavril-Parfene C, Cozinov A, Olteanu R, Craiu D. Antenatal Cerebral Hemorrhages: Evolution and Outcome. Donald School J Ultrasound Obstet Gynecol 2014;8(2):208-217.

**Source of support:** Dimitrie Pelinescu-Onciul, Adrian Ioan Toma and Dana Craiu contributed equally for the paper.

**Conflict of interest:** None

## INTRODUCTION

Antenatal hemorrhage is a rare condition. There are several known causes of antenatal hemorrhage, such as coagulopathies, vascular abnormality, infection, fetal asphyxia, fetal trauma or tumors.<sup>1,2</sup> But, in most of the cases, the cause remains unknown.<sup>1,2</sup>

Antenatal hemorrhage can be detected before delivery or after the birth of a symptomatic or asymptomatic neonate. Before delivery, the diagnosis can be established by ultrasound if acute changes of fetal well-being or acute maternal event appeared.<sup>1</sup> After delivery, the neonate can be symptomatic or asymptomatic, depending on the onset of hemorrhage.<sup>3</sup> If the hemorrhage occurs a week to several weeks or months before delivery, the symptoms can be absent or the patient can be in the stage of sequelae (known as static profile).<sup>3</sup> If the antenatal event occurs shortly before the delivery, the symptoms are usually acute with signs of perinatal depression. This is known as the dynamic profile (Fig. 1).<sup>3</sup>

Brain imaging (usually ultrasound in the neonatal period) can establish the diagnosis,<sup>1,2,4</sup> and help to establish the prognosis, based on the affected region.<sup>5-7</sup> It may also establish the time of occurrence of the hemorrhage<sup>1</sup> (Table 1).

The present paper has two parts as follows:

- The first half—the usefulness of the head ultrasound screening in term neonates is discussed.
- The second part—three cases of antenatal cerebral hemorrhage in neonates are presented and discussed. The discussions will answer, in each case, five questions:
  - When did the hemorrhage occur?
  - What was the diagnosis?
  - Were there any neonatal consequences?
  - Were other lesions present?
  - What was the prognosis of cerebral hemorrhage?

The aim of the study is to investigate if neonatal head ultrasound can be used as a screening test for detection of brain hemorrhage in a population of term neonates.

## PATIENT AND METHODS

Term neonates were examined by head ultrasound on days 1 and 3 of life. Prenatal histories and ultrasound results were collected in all cases. A neurological examination (Amiel-Tison neurologic exam for newborns<sup>3</sup>) was also performed on days 1 and 3. In cases with abnormal ultrasound examinations on days 1 and 3, head ultrasound was scheduled at the age of 1, 2, 4 and 6 months. Additionally, in these cases, specific imaging and neurological investigations (based on clinical judgment) were performed at the age of 1, 2, 4, 6, 12 months and 2 years.

<sup>1</sup>Professor, <sup>2,8</sup>Associate Professor, <sup>3-7</sup>Senior Physician

<sup>1</sup>Department of Obstetrics and Gynecology, University of Medicine and Pharmacy 'Carol Davila', Bucharest; Medical Director, Life Memorial Hospital, Bucharest, Romania

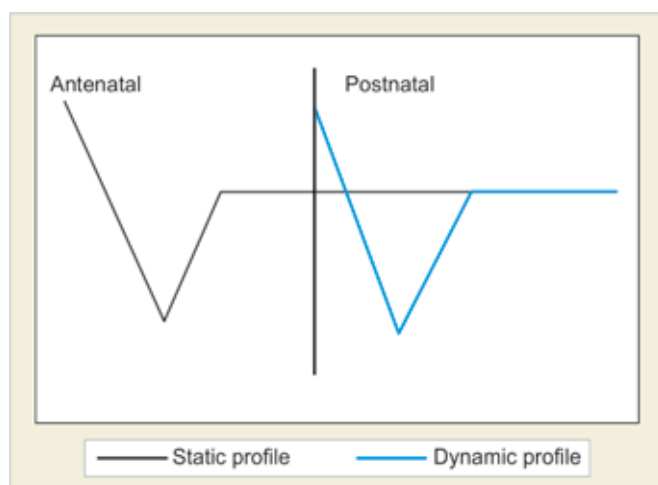
<sup>2</sup>Department of Neonatology, Pediatrics and Child Care Titu Maiorescu University, Faculty of Medicine, Bucharest; Coordinator of the Department of Neonatology, Life Memorial Hospital, Bucharest; Pediatric Neurologist, Life Memorial Hospital Bucharest, Romania

<sup>3,5</sup>Department of Obstetrics and Gynecology, Life Memorial Hospital, Bucharest, Romania

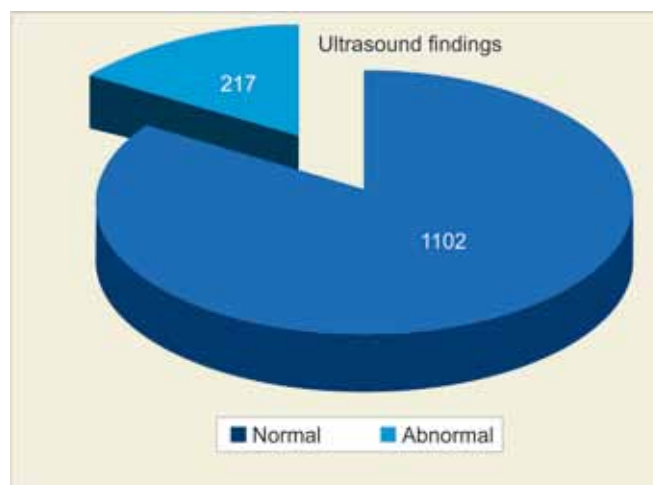
<sup>4,6,7</sup>Department of Neonatology, Life Memorial Hospital Bucharest, Romania

<sup>8</sup>Department of Pediatric Neurology, University of Medicine and Pharmacy 'Carol Davila', Bucharest; Chief of the Pediatric Neurology Unit, Alexandru Obregia Hospital, Bucharest, Romania

**Corresponding Author:** Adrian Ioan Toma, Associate Professor Life Memorial Hospital, 365, Calea Grivitei, Sector 1, Bucharest Romania, Phone: +40-212094031, e-mail: atoma@medlife.ro



**Fig. 1:** Static and dynamic profile of the evolution of the neurologic symptoms



**Fig. 2:** Number of cases with abnormalities of the neonatal ultrasound

## RESULTS

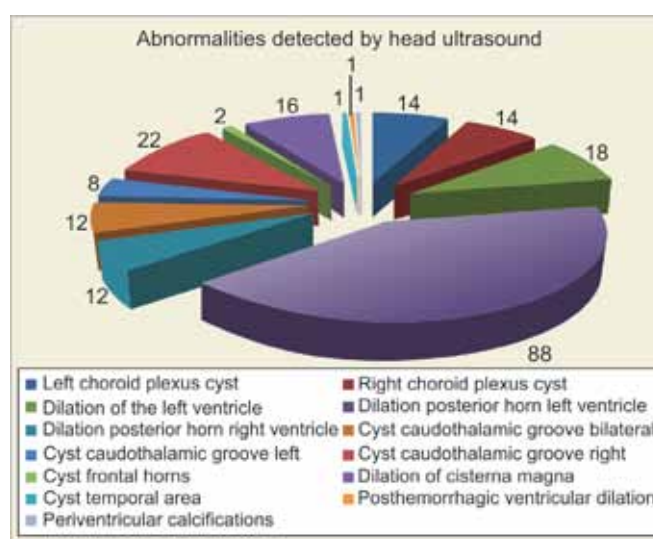
Head ultrasound examinations were performed in 1,319 neonates born at term. The mean gestational age of the group was 38.5 weeks (37-41 weeks), and the mean birth weight was 3,350 gm ( $\pm 549$  gm).

Ultrasound examinations revealed normal finding in 1,102 neonates (83.54%) (Fig. 2). The most frequently identified abnormalities were: dilation of the posterior horn of the left ventricle (88 cases), cystic formations at the level of the right caudothalamic groove (22 cases) and dilation of the left ventricle (18 cases) (Table 2 and Fig. 3).

Of the cases with a normal head ultrasound, 15 had an abnormal neurological exam at day 3 of life (Table 3). Of these, six had neurological abnormalities during follow-up.

Of the cases with ultrasound abnormalities, patients with choroid plexus cysts and patients with dilation of cisterna magna had a normal result for the neurological examination.

All patients with ventricular dilation were asymptomatic during the neonatal period and only six of the 88 cases diagnosed with left posterior horn dilation and one of the cases with right posterior horn dilation developed neurological abnormalities (*see* Table 3). All these cases were identified antenatally.



**Fig. 3:** Type of abnormal findings on neonatal head ultrasound

Of all cases with cystic formations at the level of the left caudothalamic groove, 15 were asymptomatic. One asymptomatic case and five symptomatic cases presented abnormalities during the follow-up. Six cases with bilateral cysts were asymptomatic and one developed a hypotonic syndrome (the mother had Crohn's disease and the patient had a personal history of fetal heart rhythm abnormalities).

**Table 1:** Timing of the cerebral hemorrhage/ultrasound findings (modified after Govaert P<sup>1</sup>)

Stage	Time from hemorrhage	Appearance of the lesion
Hyperacute	0-6 hours	Cerebrospinal fluid hypoechoic, particulate with motion
Acute	6-72 hours	Hyperechoic
Subacute (early)	4-10 days	Hyperechoic image with hypoechoic center
Subacute (late)	10-21 days	Clot—hypoechoic center and white border Ependima—hyperechoic
Late	After 22 days	Porencephalic cyst

**Table 2:** Ultrasound abnormalities observed at neonatal head ultrasound and association with abnormal neurologic findings in the neonatal period and on follow-up

<i>Ultrasound findings</i>	<i>Total number</i>	<i>Normal neurologic exam— neonatal/ total of cases</i>	<i>Abnormal neurologic examination— neonatal/total of cases</i>	<i>Abnormal neuro-developmental findings on follow-up/total of cases</i>
Normal	1102	1087/1102	15/1102	6/1102
Coroid plexus cyst—left	14	14/14	0/14	0/14
Choroid plexus cyst—right	14	14/14	0/14	0/14
Dilation of the left ventricle	18	18/18	0/18	0/18
Dilation posterior horn—left ventricle	88	88/88	0/88	6/88
Dilation of posterior horn—right ventricle	12	12/12	0/12	1/12
Cyst caudothalamic groove—bilateral	12	6/12	6/12	1/12
Cyst caudothalamic groove—right	8	8/8	0/8	0/8
Cyst caudothalamic groove—left	22	15/22	7/22	6/22
Cysts—anterior horns	2			
Dilation of cisterna magna	16	16/16	0/16	0/16
Cyst—temporal area	1	0/1	1/1	1/1
Post-hemorrhagic dilation of the ventricles and porencephalic cyst	1	0/1	1/1	1/1
Small periventricular calcifications	1	0/1	1/1	1/1

**Table 3:** Total of cases with neurologic abnormalities. Total of cases with abnormalities of follow-up that would have been missed without a neonatal head ultrasound (last column)

<i>Ultrasound findings</i>	<i>Abnormal neuro-developmental findings on follow-up/total of cases</i>	<i>Abnormal neurologic examination - neonatal/total of cases</i>	<i>Abnormalities identified in the fetal life (imaging/fetal well-being)/ total of cases</i>	<i>Total cases with neurological abnormalities identified with abnormalities other than neonatal ultrasound/total of cases identified</i>	<i>Cases that would have been missed without an ultrasound in the neonatal period/total of cases identified</i>
Normal	6/1102	6/1102	5/1102	6/6	0
Dilation posterior horn—left ventricle	6/88	0/88	78/88	6/6	0
Dilation of posterior horn—right ventricle	1/12	0/12	1/12	1/1	0
Cyst caudothalamic groove—bilateral	1/12	6/12	0/12	1/11	0
Cyst caudothalamic groove—right	0/8	0/8	0	0	0
Cyst caudothalamic groove—left	6/22	7/22	4/22	6/6	0
Cyst—temporal area	1/1	1/1	0/1	1/1	0
Post-hemorrhagic dilation of the ventricles and porencephalic cyst	1/1	1/1	1/1	1/1	0
Small periventricular calcifications	1/1	1/1	0/1	1/1	0

All the cases with right caudothalamic grow cystic formations were asymptomatic, both in the neonatal period and on follow-up.

The cases with small cysts at the level of the right temporal area, posthemorrhagic dilation of the lateral ventricles and left cyst and small periventricular calci-

fications were all diagnosed *in utero* (see Fig. 3, Tables 2 and 3).

## CONCLUSION

The following conclusions can be drawn from this study:

1. A normal head ultrasound in the neonatal period, in the setting of an abnormal neurologic exam, is not a conclusive finding.
2. More than 15% of the neonates born at term had abnormal finding on ultrasound examination in the newborn period, but less than 5% of the lesions were clinically significant.
3. In all these cases, either clinical examination was abnormal or there were abnormalities on the fetal ultrasound or of the fetal well-being assessment.
4. In the case of appropriate follow-up of the pregnancy and labor and of appropriate neonatal neurologic assessment, the head ultrasound screening is not recommended in asymptomatic newborns.

## CASE REPORTS

### Case 1

Antenatal Cerebral Hemorrhage in the Germinal Matrix, Intraventricular Hemorrhage and Periventricular Hemorrhagic Infarction

This is the case of a female newborn, born at gestational age of 36 weeks. Fetal ultrasound examination was normal at 28 weeks of gestation (Fig. 4). At 32 weeks, the fetal head ultrasound revealed bilateral ventricular dilation and presence of clot within the ventricles (Fig. 5). The diagnosis of fetal periintraventricular hemorrhage was established. The patient was delivered at 36 weeks.

The newborn had a normal clinical neurologic examination, corresponding to the gestational age. The head

ultrasound showed unilateral dilation of the left lateral ventricle (both frontal and occipital horns) and the presence of inhomogeneous mass with echolucent areas, periventricularly, on the roof of the left ventricle, at the level of the left parietal lobe, suggestive of post-hemorrhagic infarction (Figs 6A and B). In evolution, left porencephalic cyst communicating with the body of the left lateral ventricle occurred (Figs 7A and B).

### When did the Hemorrhage occur?

The hemorrhage occurred antenatally between 28 and 32 weeks of gestation. The fetal ultrasound was normal at 28 weeks but showed the dilation of the lateral ventricles and the presence of the periintraventricular clot at 32 weeks.

### What is the Diagnosis?

The correct diagnosis is antenatal periintraventricular hemorrhage (Volpe grade 3) and left periventricular hemorrhagic infarction.

### Are There Neonatal Consequences?

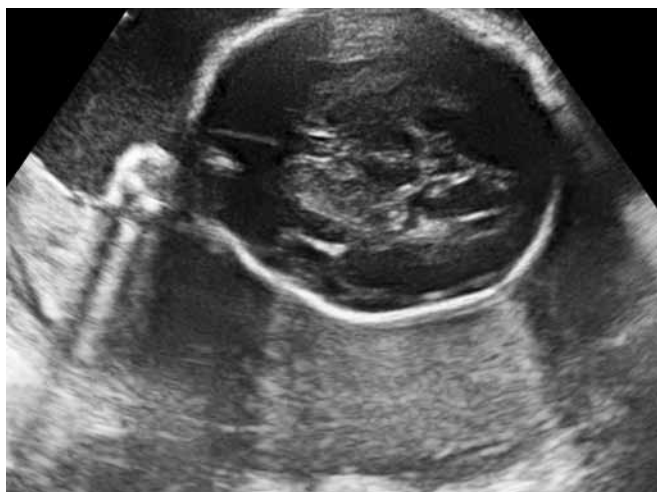There were no neurologic signs in the neonatal period. We witnessed a static clinical profile (the lesion occurred several weeks before delivery). The clinical examination in the neonatal period was normal.

### Other Lesions?

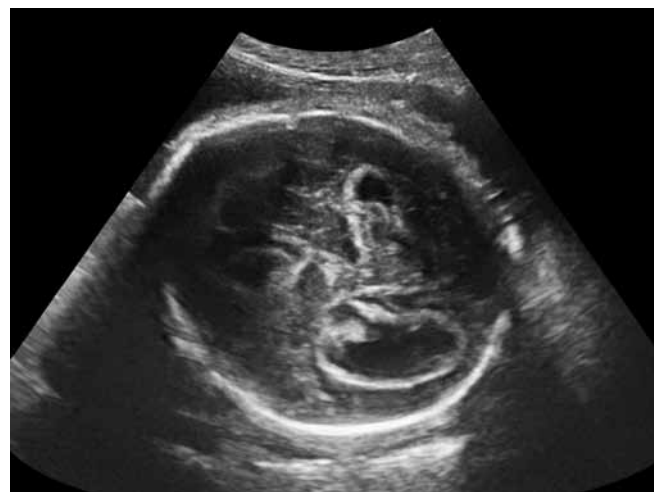The left periventricular hemorrhagic infarction could be considered as a lesion associated with the periventricular hemorrhage.

### What is the Prognosis?

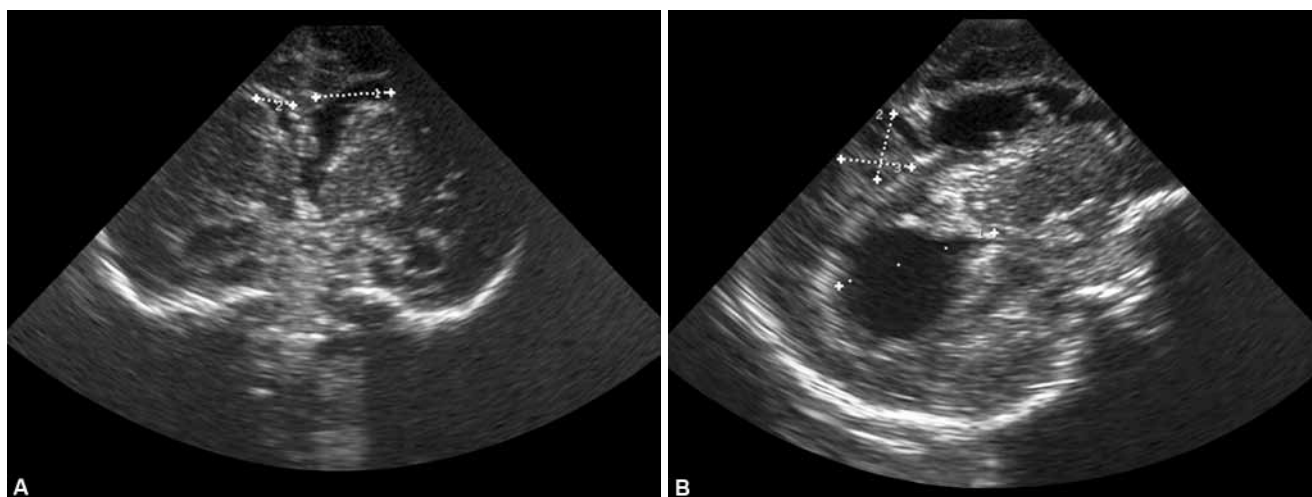
Based on the type of the lesion (hemorrhage affecting the growing brain of the fetus) and anatomical localization (left



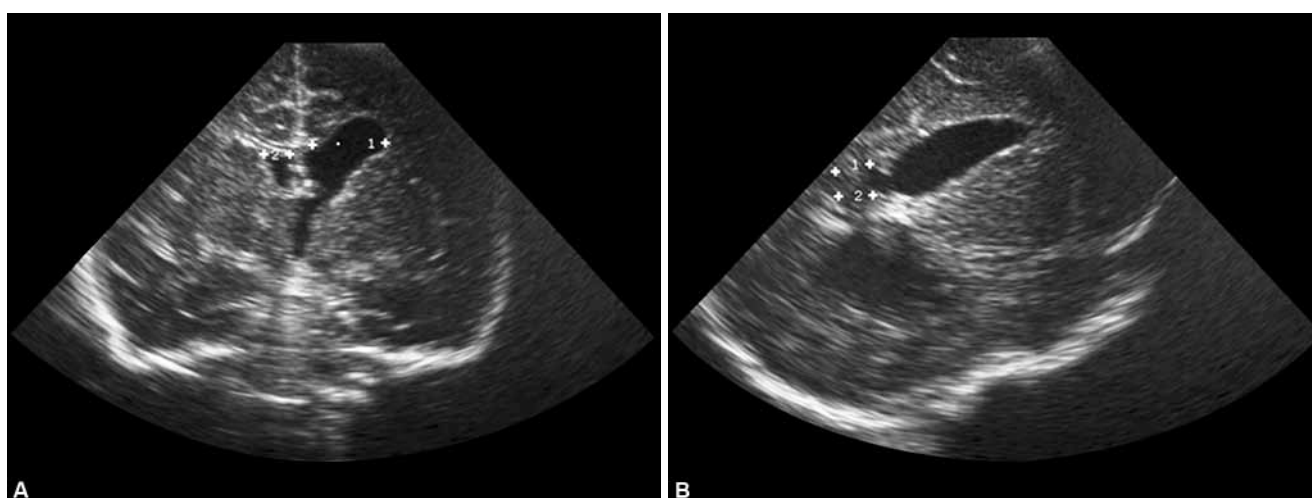
**Fig. 4:** Case 1: Normal fetal head ultrasound at 22 weeks gestational age. Normal transthalamic section with normal size of both lateral cerebral ventricles



**Fig. 5:** Case 1: Fetal head ultrasound at 32 weeks gestational age. Ventricular dilation and intraventricular clot. Bilateral hyperechogenic fields inside cerebral ventricles [Ventriculomegaly—IVH (intraventricular hemorrhage grade III), normal BPD (biparietal diameter) and HC (head circumference)]



**Figs 6A and B:** Case 1: Postnatal head ultrasound performed in day 1 of life. Coronal section showing unilateral left ventricular dilation (panel A) and parasagittal section showing unilateral left ventricular dilation and left parietal porencephalic cyst (panel B)



**Figs 7A and B:** Case 1: Postnatal head ultrasound performed at the age of 2 months. Coronal section showing unilateral left ventricular dilation persists (panel A) and parasagittal section showing unilateral left ventricular dilation. Porencephalic cyst communicating with left lateral ventricle (panel B)

parietal lobe, probably primary motor and secondary motor area) at that moment, we could anticipate the following possible consequences:

- Microcephaly<sup>8-10</sup>—the destructed tissue was probably represented by neurons and precursors of the neurons; their destruction lead to the absence of formation of certain areas in the brain, and to a reduction in the brain and skull volume.
- Hydrocephalus<sup>11-13</sup> could develop due to the obstruction of the cerebrospinal fluid flow between the ventricles. Usually, this occurs during the first 4 to 8 weeks after the hemorrhage, so this is less probable.
- Motor deficit at the level of the right half of the body<sup>9,10,13</sup> (corresponding to a lesion of the left side of the brain). resulting usually in unilateral spastic cerebral palsy.
- Mental deficit due to destruction of neuronal precursors.<sup>8-10,14</sup>

## Evolution of the Case

The growth pattern of the head circumference decreased (Fig. 8).<sup>15</sup>

The patient began physical therapy during the first months of life.

Neurologic examination at 8 months showed the following: the patient sustained her head and sat on her one. She followed appropriately with the eyes and had good eye contact, good social interaction and recognized others. The neurologic motor examination showed asymmetric tone and posture, hypertonicity at the level of the right arm, with flexion and internal rotation of the arm, but the patient passed toys from one hand to the other. The right leg was hypertonic, with brisk deep tendon reflexes, but no clonus. The diagnosis was unilateral spastic cerebral palsy with no mental retardation.



The patient is currently involved in physical therapy program.

## Case 2: Postnatal Diagnosis of an Antenatal Hemorrhage

This is the case of a female newborn, born by cesarean section at 39 weeks of gestation. The mother has Crohn's disease and is under treatment with salazopyrin. The mother was admitted to the hospital 2 weeks before delivery, because of abnormalities of fetal movements, associated with a respiratory infection. The newborn had a normal neurologic examination in the neonatal period. Head ultrasound was performed on day 3 of life as part of a study of normal ultrasounds in newborns.

The head ultrasound showed bilateral cysts of the head of caudate nucleus (Figs 9A to C). Following ultrasound examinations showed the evolution of the lesion, until the disappearance of the cysts, suggesting the evolution of a periventricular hemorrhage (Figs 10A and B).

### When did the Hemorrhage occur?

The stage of the lesion at the time of the diagnosis suggests that the hemorrhage occurred at least 10 to 14 days before the ultrasound examination, approximately 10 days before delivery.

### What is the Diagnosis?

The ultrasound diagnosis is bilateral germinal matrix-intraventricular hemorrhage (grade 1-2 Volpe). Bilateral hemorrhage is located in both heads of caudate nucleus and is associated with mild ventricular dilation.

### Are There Neonatal Consequences?

There are no apparent neonatal clinical signs related to the hemorrhage. The lesion was diagnosed during routine examination.

### Other Lesions?

Such a lesion seldom occurs at 38 weeks of gestation, while it is more often seen in premature infants from 28 to 32 weeks of gestation<sup>16,17</sup>. A possible cause could be represented by the presence of maternal and neonatal coagulation abnormalities<sup>18-21</sup> (in this case, both the coagulation tests in the mother and the neonate were normal) or abnormalities in the blood pressure (not seen).<sup>4</sup> Such a severe insult that can cause a hemorrhage at that age could also cause other lesions which are not apparent in this neonate.

### What is the Prognosis?

At the moment of the diagnosis, prognosis could not be made with certainty. The patient needs to be included in a follow-up program. If the lesion is just a grade 1 hemorrhage,

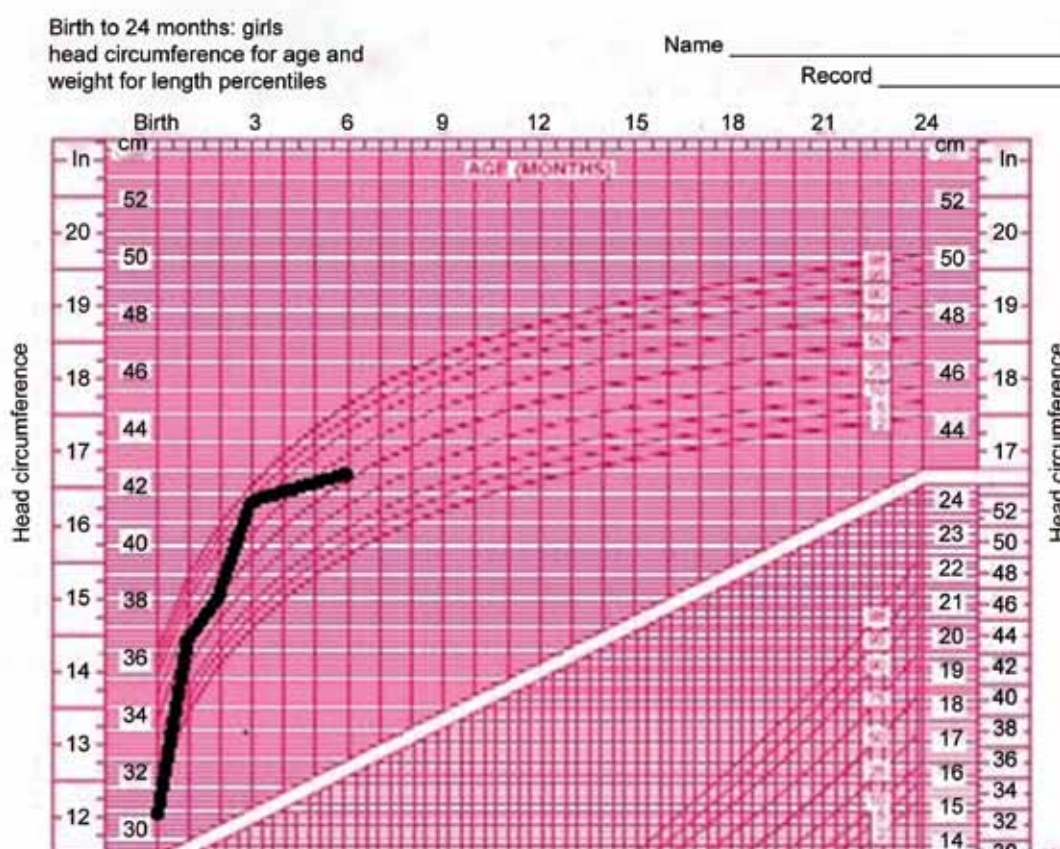
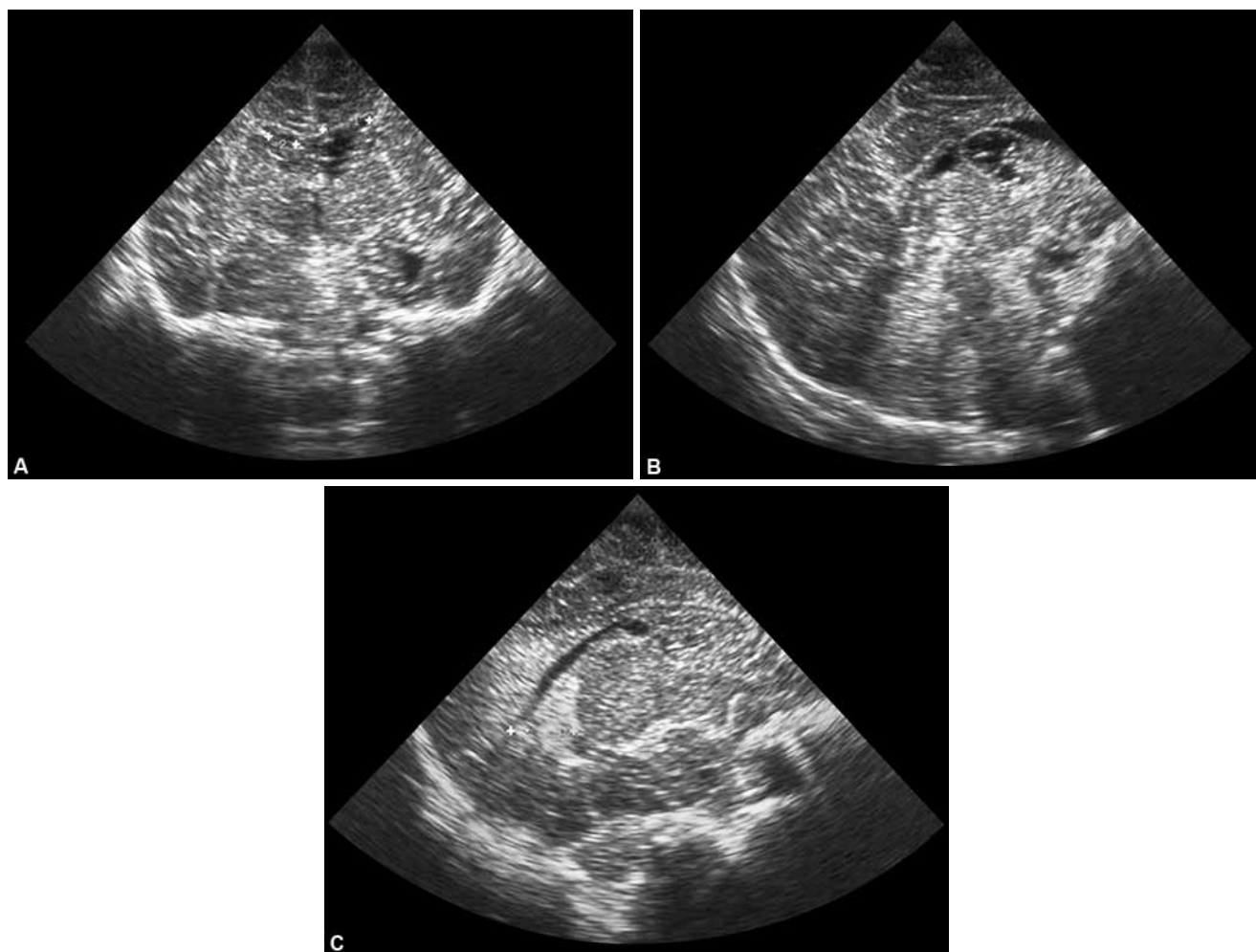
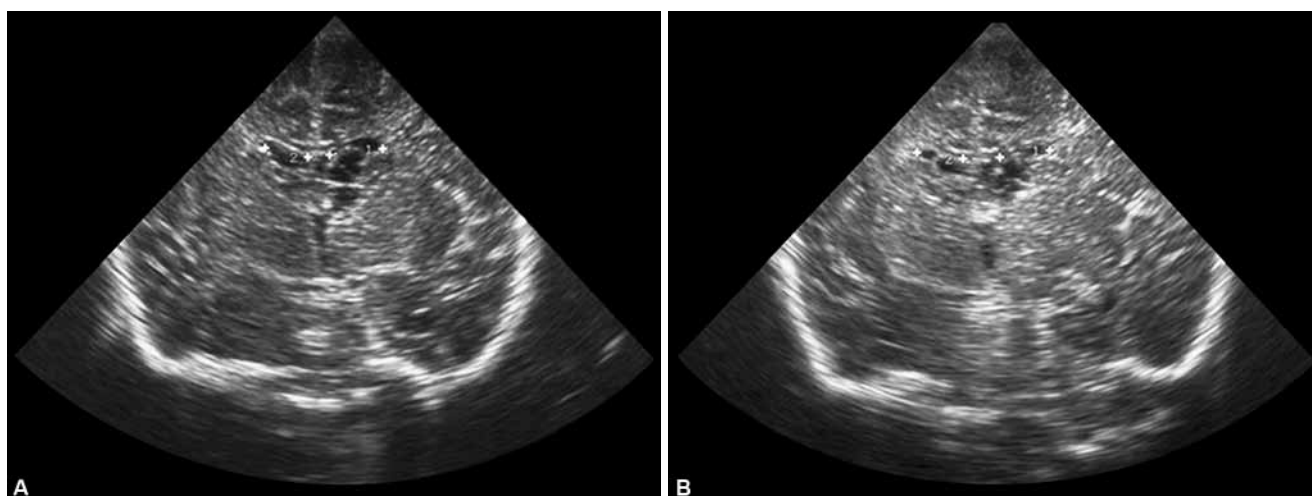


Fig. 8: Case 1: Evolution of the head circumference



**Figs 9A to C:** Case 2: Head ultrasound in the neonatal period (day 3 of life). Multicystic images at the level of the caudate nucleus bilateral are visible in coronal section (panel A). In parasagittal section are visible—the left (panel B) and right (panel C) ventricles



**Figs 10A and B:** Case 2: Head ultrasound in evolution showing a multicystic image at the level of the caudate nucleus bilateral at 1 month (panel A) and 2 months (panel B)

the prognosis is good. The problem is if the hemorrhage is a sentinel lesion. There could be a risk for hydrocephalus and also for microcephaly and mental retardation (see discussion on case 1).

### Evolution of the Case

At the age of 8 months, the neurologic examination of the infant was abnormal. The control of the head was present, but there was head lag. The patient did not sit alone and did



not lift the head in prone position. She had periods with no visual contact.

No seizures were noted in the evolution. The electroencephalographic examination was repeatedly normal for the age.

The growth of head was normal for the age (Fig. 11<sup>15</sup>).

The patient is currently in a program of physical and occupational therapy.

### Case 3: Hyperechogenicity in the Thalamus—Stroke or Hemorrhage?

Female newborn born by cesarean section is presented. The patient had an Apgar score of 8 (−1 color; −1 muscle tone) and did not need ventilation at delivery. Until day 2 of life, she was considered by the attending physician as a normal, but quiet baby.

On day 2 of life, the attending physician observed torticollis (a deviation of the head to the right) which was treated by positioning. On day 3 of life muscular tone and gaze abnormalities appeared: opisthotonos, lateral deviation of both eyes, hypertonicity of the hands and feet.

The laboratory tests assessing complete blood count, blood culture, glucose, sodium, calcium, magnesium and potassium levels were within normal range; the lumbar puncture showed normal CSF, normal chemistry, cultures were negative.

The head ultrasound (Figs 12A to E) showed a hyperechogenic image at the level of the left thalamus, which transformed into a cyst during the first 2 weeks of life.

#### When did the Hemorrhage occur?

The onset of hemorrhage was probably perinatal, at the time of diagnosis, the hemorrhage was probably 5 to 7 days old, according to the ultrasound examination.

#### What is the Diagnosis?

Due to the anatomic localization and the ultrasound appearance of the lesion, the most probable diagnosis is hemorrhage at the level of the thalamus and the basal ganglia.

#### Are There Neonatal Consequences?

In this case, we are facing a dynamic profile.<sup>3</sup> The baby was depressed at birth, 'quiet'—meaning loss of reactivity, the dystonic postures (torticollis, opisthotonus) and dystonia of the eyes probably occurred as the hemorrhage progressed.

#### Other Lesions?

At the moment of the diagnosis, no other associated lesions were identified.

#### What is the Prognosis?

Unfortunately, the patient was lost for follow-up at 4 months of age.

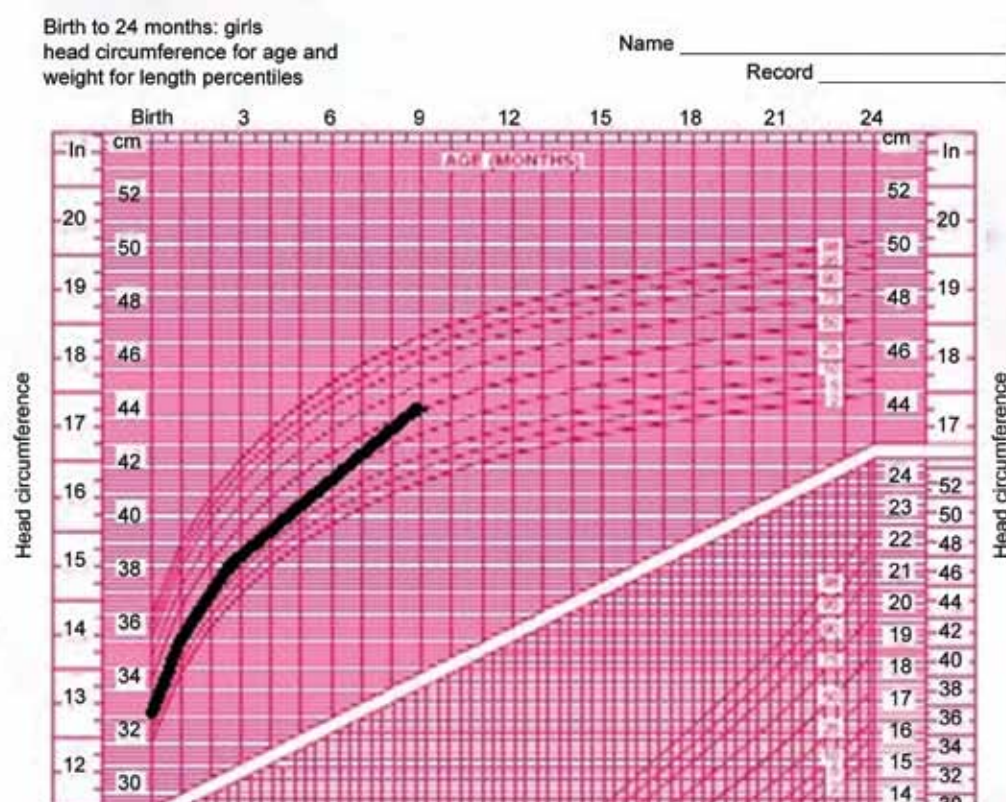
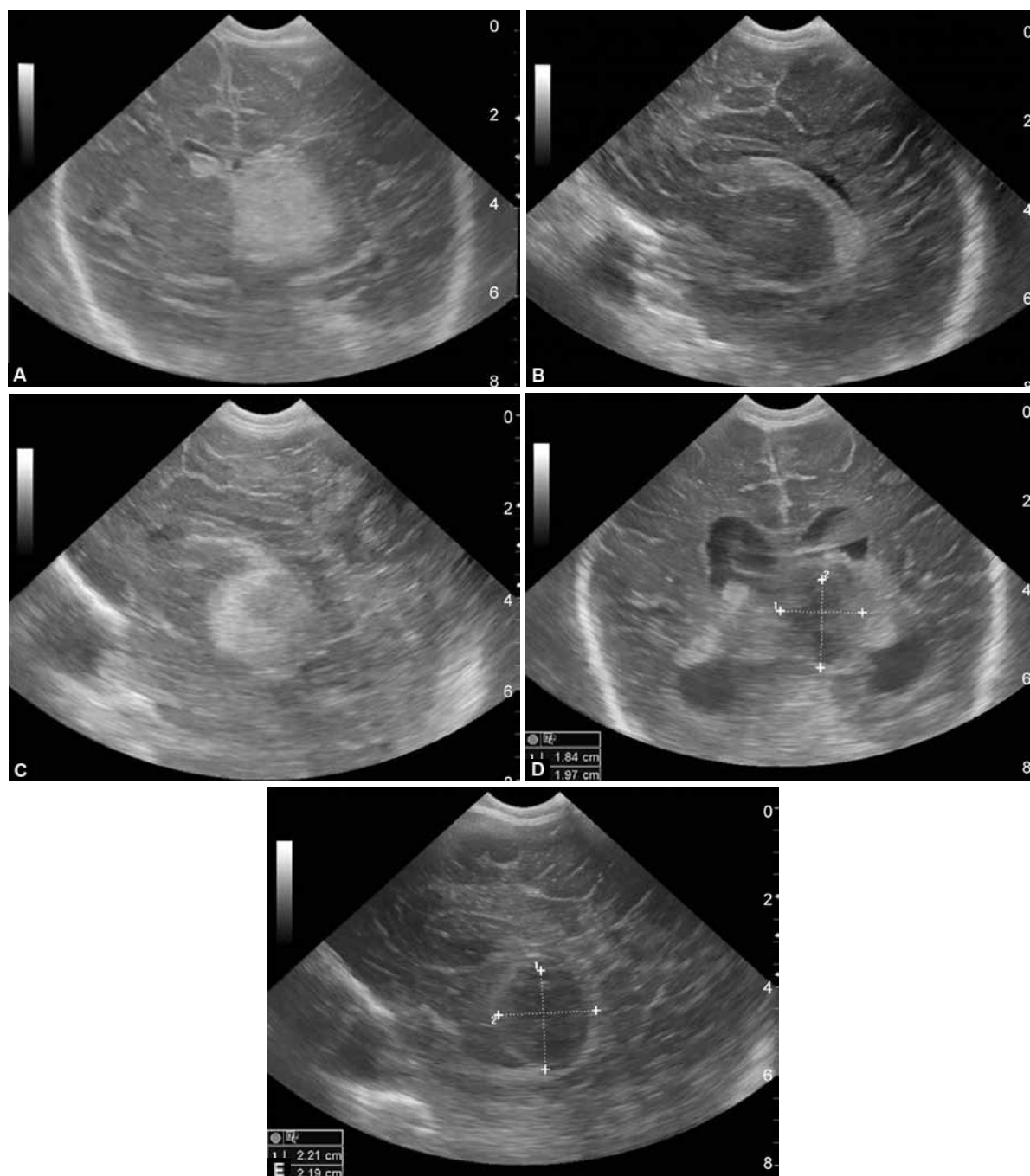


Fig. 11: Case 2: Evolution of the head circumference





**Figs 12A to E:** Case 3: Head ultrasound—unilateral thalamic hemorrhage in evolution. Hyperechogenic image at the level of the left thalamus and basal ganglia (day 5 of life; coronal section—panel A; parasagittal section—panel C), normal image of the right lateral ventricle (parasagittal section; day 5 of life; panel B). At day 14 of life, in parasagittal section is visible, the cystic transformation of the previous left hyperechogenic image (panel D). Same image and bilateral ventricular dilation observed in coronal section during day 19 of life (panel E)

Based on the anatomic localization of the lesion, we could speculate of the risk of mental retardation<sup>22</sup> and the risk of mixed cerebral palsy (spastic and dystonic type).<sup>4</sup>

## CONCLUSION

The causes of fetal cerebral hemorrhages could not be clearly established in our case-series. Known causes are represented by antenatal hypoxic-ischemic events, blood coagulation abnormalities and others but, in many cases, the cause remains unknown.

Mostly cerebral hemorrhage appearing antenatally is asymptomatic in the neonatal period, as in two of presented neonates, but the patient could be symptomatic if the hemorrhage occurred perinatally, and if it is consistent with a dynamic profile.

Antenatal cerebral hemorrhage could be detected *in utero* (as in case 1, in which the hemorrhage occurred between 28 and 32 weeks of gestation). In the case of a perinatal event, the hemorrhage appears postnatal and the timing could be estimated by imaging.

As discussed, postnatal head ultrasound screening is not useful. Screening based on the assessment of risk factors (antenatal risk factors, abnormal fetal well-being tests and/or problems during labor and delivery and abnormalities of the neurologic examination) is recommended.

There are five questions to ask if one is dealing with cerebral hemorrhage in fetus or neonate, in order to establish a correct diagnosis and prognosis:

- When did the hemorrhage occur?
- What is the diagnosis?
- Are there neonatal consequences?
- Other lesions?
- What is the prognosis?

The prognosis in the case of an antenatal cerebral hemorrhage cannot be established immediately after birth. Assumptions can be made based on the anatomic location of the lesion, but the final prognosis needs longer multidisciplinary follow-up of the patient in a specialized clinic.

## ACKNOWLEDGMENTS

Authors wish to acknowledge the editorial support provided by Timea Kiss (XPE Pharma & Science).

## REFERENCES

1. Govaert P, de Vries LS. Antenatal intracranial hemorrhage. In: Govaert P, de Vries LS, editors. *An Atlas of Neonatal Brain Sonography*. 2nd edition. Mac Keith Press, 2010. p. 133-138.
2. Achiron R, Pinchas OH, Reichman B, Heyman Z, Schimmel M, Eidelman A, Mashiach S. Fetal intracranial hemorrhage: clinical significance of in utero ultrasonographic diagnosis. *Br J Obstet Gynecol* 1993;100:995-999.
3. Amiel Tison CI. *Neurologie perinatale*. Masson, Paris, 2002; 108-126.
4. Volpe JJ. *Neurology of the newborn*. 5th edition. Saunders Elsevier, 2008;483-588.
5. Guzzetta F, Shackelford GD, Volpe S, Perlman JM, Volpe JJ. Periventricular intraparenchymal echodensities in the premature newborn: critical determinant of neurologic outcome. *Pediatrics* 1986;78:995-1006.
6. Bassan H, Limperopoulos C, Visconti K, Mayer DL, Feldman HA, Avery L, Benson CB, Stewart J, Ringer SA, Soul JS, et al. Neurodevelopmental outcome in survivors of periventricular hemorrhagic infarction. *Pediatrics* 2007;120: 785-792.
7. Blackman JA, McGuinness GA, Bale JF Jr, Smith WL Jr. Large postnatally acquired porencephalic cysts: unexpected developmental outcomes. *J Child Neurol* 1991;6:58-64.
8. De Vries LS, Van Haastert IL, Rademaker KJ, Koopman C, Groenendaal F. Ultrasound abnormalities preceding cerebral palsy in high-risk preterm infants. *J Pediatr* 2004;144:815-820.
9. Wilson-Costello D, Friedman H, Minich N, Fanaroff AA, Hack M. Improved survival rates with increased neurodevelopmental disability for extremely low birth weight infants in the 1990s. *Pediatrics* 2005;115:997-1003.
10. Ahmann PA, Lazzara A, Dykes FD, Brann AW Jr, Schwartz JF. Intraventricular hemorrhage in the high-risk preterm infant: Incidence and outcome. *Ann Neuro* 1980;17:118-124.
11. Cust AE, Darlow BA, Donoghue DA. Outcomes for high risk New Zealand newborn infants in 1998-1999: a population based, national study. *Arch Dis Child* 2003;88:15-22.
12. Holt PJ, Allan WF. The natural history of ventricular dilatation in neonatal intraventricular hemorrhage and its therapeutic implication. *Ann Neurol* 1981;10:293.
13. Ment LR, Vohr B, Allan W, Westerveld M, Katz KH, Schneider KC, Makuch RW. The etiology and outcome of cerebral ventriculomegaly at term in very low birth weight preterm infants. *Pediatrics* 1999;104:243-248.
14. Rademaker KJ, Groenendaal F, Jansen GH, Eken P, de Vries LS. Unilateral haemorrhagic parenchymal lesions in the preterm infant: shape, site and prognosis. *Acta Paediatr* 1994;83: 602-608.
15. WHO Multicentre Growth Reference Study Group: WHO Child Growth Standards: Length/height-for-age, weight-for-age, weight-for-length, weight-for-height and body mass index-for-age: Methods and development. Geneva, World Health Organization, 2006. Available at: [http://www.who.int/childgrowth/standards/technical\\_report/en/index.html](http://www.who.int/childgrowth/standards/technical_report/en/index.html).
16. Szymonowicz W, Schafler K, Cussen LJ, Yu VY. Ultrasound and necropsy study of periventricular haemorrhage in preterm infants. *Arch Dis Child* 1984;59:637-642.
17. Pape KE, Wigglesworth JS. Haemorrhage, ischaemia, and the perinatal brain. JB Lippincott; Philadelphia 1979:11-38.
18. Burrows RF, Kelton JG. Low fetal risks in pregnancies associated with idiopathic thrombocytopenic purpura. *Am J Obstet Gynecol* 1990;163:1147-1150.
19. Bray GL, Luban NL. Hemophilia presenting with intracranial hemorrhage: an approach to the infant with intracranial bleeding and coagulopathy. *Am J Dis Child* 1987;141:1215-1217.
20. Ries M, Wolfel D, Maierbrandt B. Severe intracranial hemorrhage in a newborn infant with transplacental transfer of an acquired factor VIII: C inhibitor. *J Pediatr* 1995;127:649-650.
21. Sumer T, Ahmad M, Sumer NK, Al-Mouzan MI. Severe congenital factor X deficiency with intracranial haemorrhage. *Eur J Pediatr* 1986;145:119-120.
22. Sanger TS, Mink JW. Movement disorders. In: Swaiman K, Ashwal S, Ferreiro DM, Schor NF, editors. *Pediatric Neurology. Principles and Practice*. Elsevier Saunders, 2012. p. 965-998.