

Basic Diploma in International Ultrasound for Prenatal Diagnosis and Therapy

Giovanni Monni, Maria Angelica Zoppi, Ambra Iuculano

ABSTRACT

In the Microcitemico Hospital the first prenatal diagnosis in Europe of beta-thalassemia was performed in 1977 using fetal blood sampling and globin chain analysis at 20th week of gestation. Since then, more than 55,000 prenatal invasive procedures were performed in our center for several genetic and chromosomal diseases.

In 2011, our department has been introduced as a center for teaching invasive diagnostic procedures under the umbrella of the Ian Donald International University School of Medical Ultrasound. After a period of tutoring for 2 or more weeks, fellow doctors who intend to learn invasive techniques for prenatal diagnosis under the direct supervision of a senior tutor (G. Monni) can receive the basic diploma in invasive prenatal procedures (Fig. 1).

In the following study, we describe the training process of the invasive prenatal procedure performed by transabdominal chorionic villus sampling (TA-CVS).

Keywords: Invasive procedures, Transabdominal chorionic villus sampling, Diploma, Ian Donald School.

How to cite this article: Monni G, Zoppi MA, Iuculano A. Basic Diploma in International Ultrasound for Prenatal Diagnosis and Therapy. Donald School J Ultrasound Obstet Gynecol 2013;7(3):346-348.

Source of support: Nil

Conflict of interest: None declared

INTRODUCTION

In 1983, we started performing chorionic villus sampling (CVS) by transcervical route using rigid biopsy forceps but having performed it on 714 cases until 1986 we subsequently changed the technique and since then we have been adopting only the transabdominal (TA-CVS) route (Table 1) and since 1996, after the introduction of first trimester risk assessment for chromosomal diseases, the use of CVS has progressively increased.¹⁻⁴ So far, more than 150 fellow doctors have come to our Department of Obstetrics and Gynecology at Microcitemico Hospital, Cagliari, to be tutored in CVS (Fig. 2) (Table 2).⁵

Thanks to the International Ian Donald School; our department has been elected in 2011 as a center for teaching and tutoring invasive prenatal procedures and specifically CVS, amniocentesis and fetal blood sampling by cordocentesis.

We describe here the transabdominal CVS procedure the primary reason for which fellow doctors visit our center at Microcitemico Hospital in Cagliari.^{6,7}

We use the TA-CVS by free-hand technique, under ultrasound monitoring.⁸ The position of the scanner during




 <p>Dubrovnik International University Dubrovnik, Croatia</p>	 <p>Ian Donald Inter-University School of Medical Ultrasound Dubrovnik, Croatia Directors: F Chervenak and A Kurjak www.iandonaldschool.org Director of Italian Branch: Giovanni Monni</p>	 <p>Microcitemico Hospital Cagliari, Italy Department of Obstetrics and Gynecology Prenatal and Preimplantation Genetic Diagnosis, Fetal Therapy Director: Giovanni Monni</p>
<p>DIPLOMA OF INVASIVE PRENATAL PROCEDURES</p> <p>Dr.</p> <p>Has successfully passed the examination in invasive prenatal procedures under my direct tutoring</p> <p style="text-align: right;">Ian Donald Inter-University School of Invasive Prenatal Procedures Director: Giovanni Monni</p> <p>Cagliari,2013 prenatalmonni@tiscali.it</p>		

Fig. 1: Diploma Ian Donald School in invasive prenatal procedures

Table 1: Personal experience Microcitemico Hospital, Cagliari (1982-2012)

	TC-CVS*	TA-CVS**
N°	714	23,308
Weeks	9-13	6-34
Failure	1	—
Misdiagnosis	1	2
Fetal loss (%)	3	0,8

*By rigid biopsy forceps (1982-1985); **By free-hand tangential technique (1986-2012)

Table 2: Distribution of 151 fellows for CVS training at Microcitemico Hospital, Cagliari

Period	N°	%
*1983-1996	42	28
**1997-2012	109	72
	151	100

*Before NT screening; **After NT screening

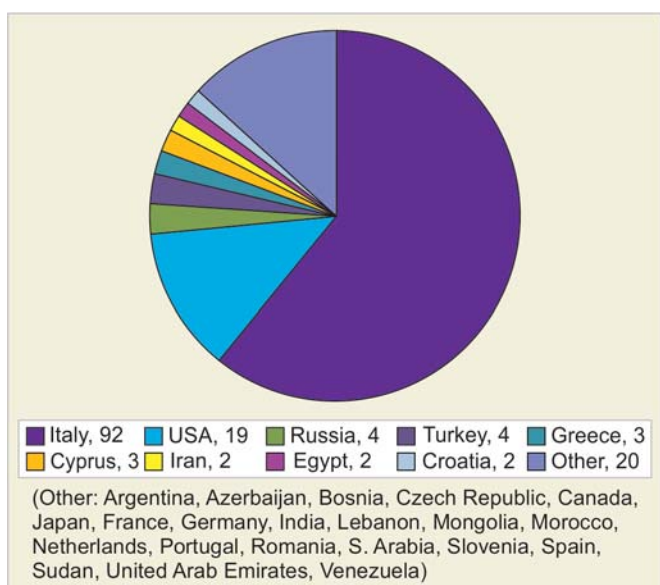


Fig. 2: A total of 151 fellows tutored at Microcitemico Hospital, Cagliari

Table 3: A total of 56,164 consecutive series in Microcitemico Hospital, Cagliari, from 1977 to 2012

	CVS	AMNIO	FBS
N°	23,308	29,842	3,014
Fetal loss (%)	0.8	0.5	2.1
Misdiagnosis	2	2	2

the introduction of the spinal needle, the possible angle of inclination, the manual tissue aspiration by a 2 ml syringe are all described in Figure 3. The sampling success in our hands is 100%. When the procedure presents a certain difficulty, changing the amount of fullness of the bladder (Fig. 4) or vaginal manipulation of the uterus by a midwife in 3 to 4% when the placenta is completely posterior and the uterus is totally retroverted it is, still, always possible to perform the sample via the transabdominal route (Fig. 5).⁹

In Table 3, we report our experience in prenatal invasive procedures.¹⁰

Fellows usually undergo 2 or 3 weeks of tutoring in our department during which they are introduced to the team of

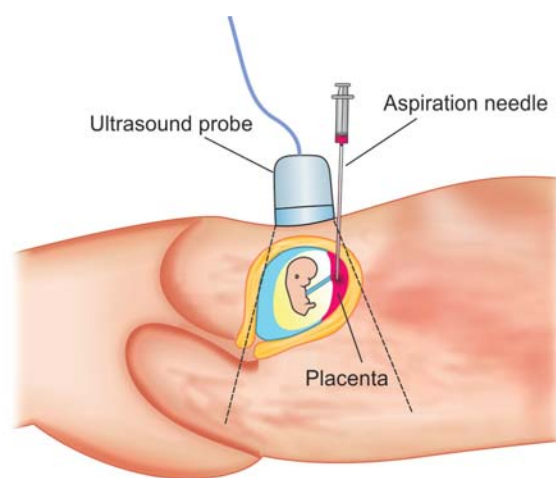


Fig. 3: TA-CVS by tangential insertion

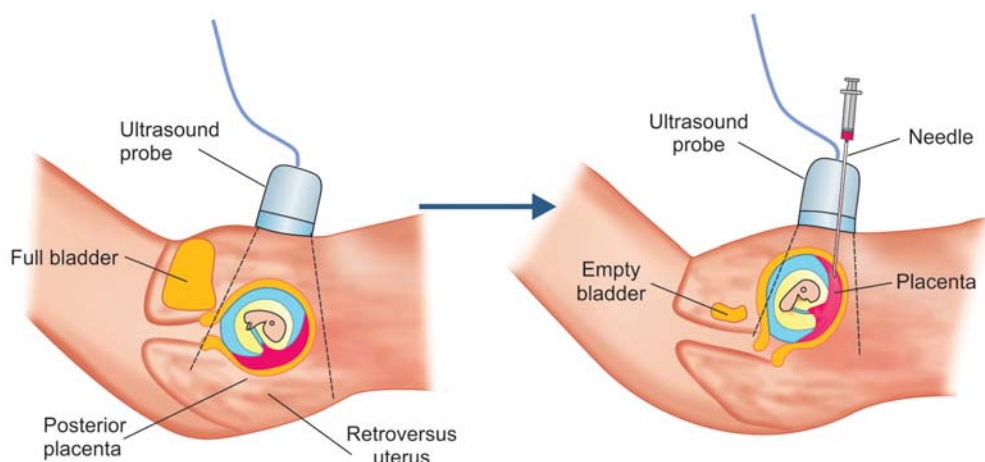


Fig. 4: TA-CVS according to the bladder

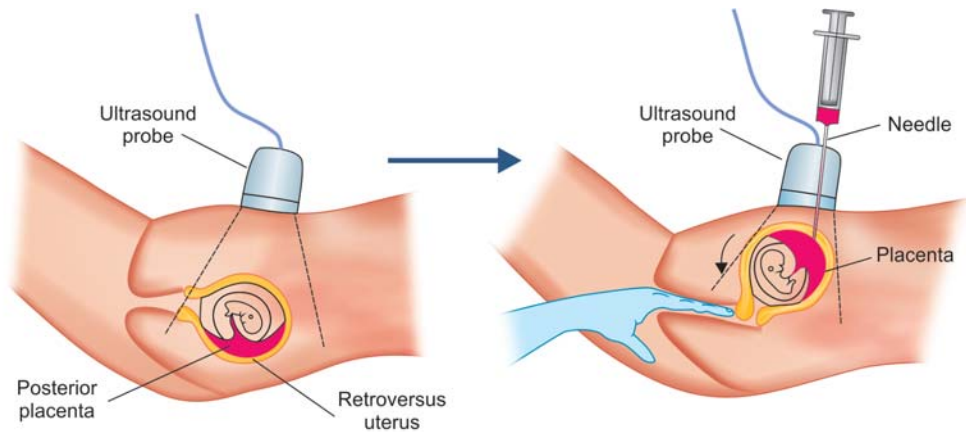


Fig. 5: Vaginal manipulation in case of posterior placenta and retroversed uterus

invasive prenatal diagnosis for Amniocenteses and TA-CVS.

Usually, during such personalized training, each fellow doctor is involved in all amniocenteses and in about 15-30 TA-CVS. The senior tutor performs TA-CVS using 20-gauge spinal needle at 11 to 12 weeks of gestation but during the tutoring the fellows start by using 18-gauge spinal needle at 12 to 13 weeks of gestation to have greater success at sampling the tissue. In 5 to 10% of cases, the senior tutor, when the sampling has not proved successful, one may repeat the TA-CVS.

Fellow doctors who have wider practice in ultrasound techniques and also in transabdominal amniocentesis prove to be more successful in learning transabdominal villus sampling technique.

The majority of fellows that, in the last years, have visited our Department of Obstetrics and Gynecology at Microcitemico Hospital, Cagliari, for training for a short period of 2 weeks have later on continued performing successfully transabdominal CVS by themselves.

REFERENCES

1. Monni G, Olla G, Cao A. Patient's choice between transcervical and transabdominal chorionic villus sampling. *Lancet*; 1(8593):1057.
2. Monni G, Ibba RM, Lai R, Cau G, Mura S, Olla G, Cao A. Transabdominal chorionic villus sampling: fetal loss rate in relation to maternal and gestational age. *Prenat Diagn* 1992;12(10):815-820.
3. Monni G, Ibba RM, Lai R, Cau G, Mura S, Olla G, Rosatelli C, Cao A. Early transabdominal chorionic villus sampling in couples at high genetic risk. *Am J Obstet Gynecol* 1993 Jan;168(1 Pt 1):170-173.
4. Wijnberger LD, van der Schouw YT, Christiaens GC. Learning in medicine: chorionic villus sampling. *Prenat Diagn* 2000;20:241-246.
5. Monni G, Zoppi MA, Axiana C, Ibba RM. Changes in the approach for invasive prenatal diagnosis in 35,127 single cases

at a single center from 1977 to 2004. *Fetal Diagn Ther* 2006;21:348.

6. Nizard J, Duyme M, Ville Y. Teaching ultrasound-guided invasive procedures in fetal medicine: learning curves with and without an electronic guidance system. *Ultrasound Obstet Gynecol* 2002;19:274-277.
7. Pittini R, Oepkes D, Macrury K, Reznick R, Beyene J, Windrim R. Teaching invasive perinatal procedures: assessment of a high fidelity simulator-based curriculum. *Ultrasound Obstet Gynecol* 2002 May;19:478-483.
8. Monni G, Zoppi MA, Ibba RM. Prenatal genetic diagnosis through chorionic villus sampling. In: Milunsky A, editors. *Genetic disorders and the fetus: diagnosis, prevention, treatment*. 6th ed. Wiley-Blackwell Publisher; 2010. p. 160-193.
9. Monni G, Zoppi MA, Axiana C. Chorionic villus sampling. *Clinical maternal-fetal medicine*. 2nd ed. In: Winn HN, Chervenak FA, Romero R, editors. Essex: United Kingdom, Informa Healthcare; 2011. p. 62.1-62.10.
10. Monni G, Zoppi MA. Improved first-trimester aneuploidy risk assessment: an evolving challenge of training in invasive prenatal diagnosis. *Opinion, Ultrasound Obstet Gynecol* 2013; 41:486-488.

ABOUT THE AUTHORS

Giovanni Monni (Corresponding Author)

Director of Ian Donald International University School of Medical Ultrasound, Department of Obstetrics and Gynecology, Prenatal and Preimplantation Genetic Diagnosis - Fetal Therapy, Ospedale Microcitemico, Cagliari, Italy, Phone: 0039 70 6095546; Fax: 0039 70 6095514; Cell. 0039 336691120, e-mail: prenatalmonni@tiscali.it

Maria Angelica Zoppi

Gynecologist, Department of Obstetrics and Gynecology, Prenatal and Preimplantation Genetic Diagnosis, Fetal Therapy, Ospedale Microcitemico, Cagliari, Italy

Ambra Iuculano

Gynecologist, Department of Obstetrics and Gynecology, Prenatal and Preimplantation Genetic Diagnosis, Fetal Therapy, Ospedale Microcitemico, Cagliari, Italy